Anatomy of Anterior Abdominal Wall and Peritoneum

Prof Dr Mohamed El-Badry Mohamed

Professor and Head of Human Anatomy and Embryology Department, Faculty of Medicine, Merit University

Professor of Human Anatomy and Embryology Department, Faculty of Medicine, Assiut University

Objectives of the of the Lecture

By the end of the lecture the student should be able to:

- Mention the layers forming the anterior abdominal wall
- Describe structure of anterior abdominal wall
- Mention blood vessels, nerve supply and lymphatic drainage of anterior abdominal wall
- Describe anatomy of the fascia of anterior abdominal wall
- Describe anatomy of the muscles of anterior abdominal wall
- Describe anatomy of the inguinal canal, boundaries and contents
- Describe anatomy of the rectus sheath, boundaries and contents
- What are the abdominal planes?
- Enumerate the organs are passed by transpyloric plane?
- Define peritoneum and name its parts and their definitions
- Name the abdominal regions
- What is the nerve supply of peritoneum
- What is the function of greater omentum of the stomach

STRUCTURE OF ABDOMINAL WALLS:

Superiorly: Diaphragm:

Separates abdominal cavity from thoracic cavity

Inferiorly: Continues with pelvic cavity through pelvic inlet

Anteriorly:

- **Above:** Lower part of thoracic cage
- **Below:** Rectus abdominis, external oblique, internal oblique and transversus abdominis muscles and fascia

Posteriorly: The 5 lumbar vertebrae and their intervertebral discs

Laterally:

- The 12th ribs, upper part of bony pelvis, psoas and quadratus lumborum muscles and aponeurosis of origin of transversus abdominis muscles
- Iliacus muscle in upper part of bony pelvis

STRUCTURE OF ANT. ABDOMINAL WALL:

1. SKIN
2. SUPERFICIAL FASCIA
3. DEEP FASCIA?
4. MUSCLES
5. EXTRAPERITONEAL FASCIA
6. PARIETAL PERITONEUM

Nerve (Cutaneous Nerve) Supply

Anterior rami of lower 6 thoracic nerves:

(Lower 5 intercostal and subcostal nerves)

Supply:

- Skin of anterior abdominal wall
- Parietal peritoneum
- External oblique muscle of abdomen
- Internal oblique muscle of abdomen
- Transverse abdominal muscle
- Rectus abdominis muscle
- Pyramidalis (T12 only)

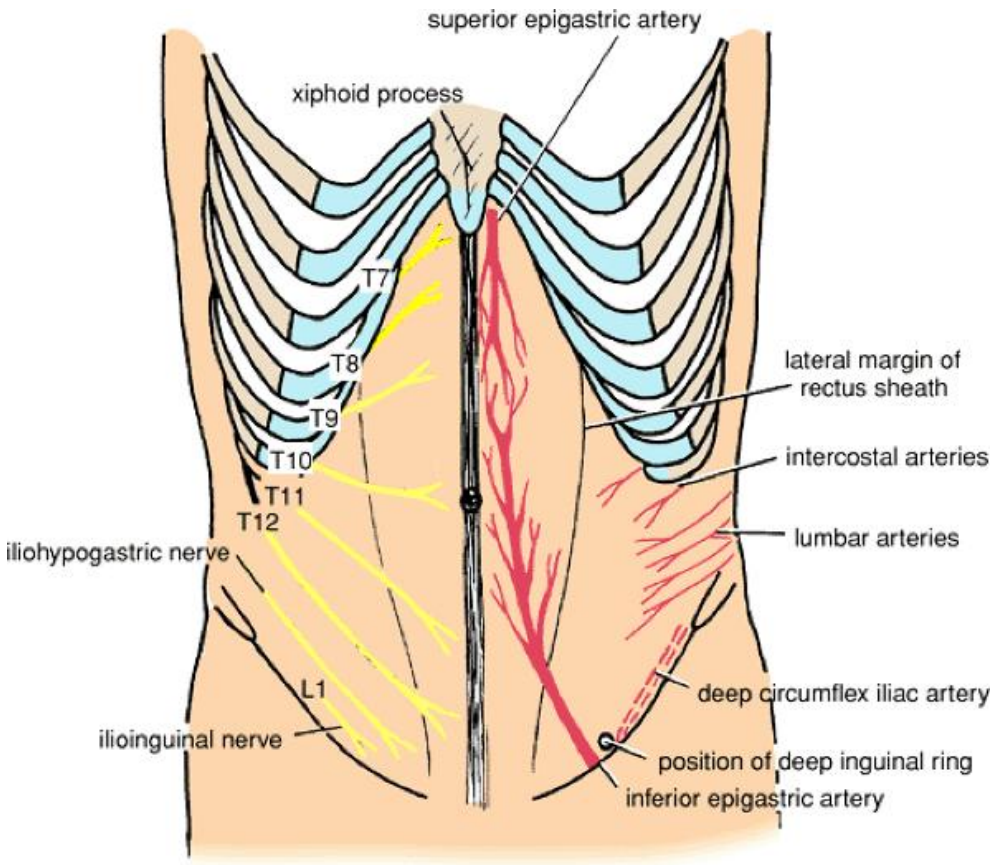

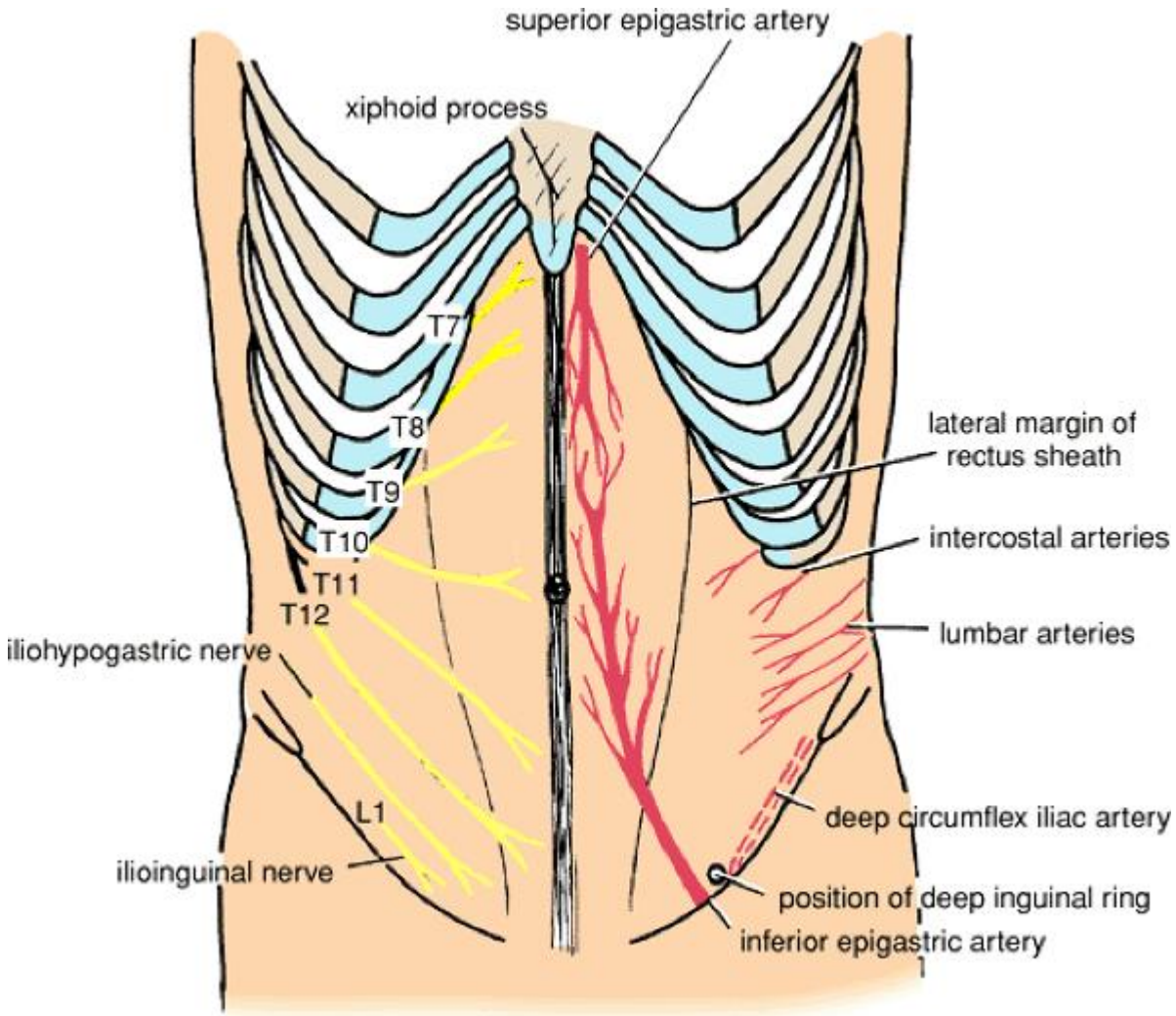
superior epigastric artery
xiphoid process
T7
T8
T9
T10
T11
T12
iliohypogastric nerve
L1
ilioinguinal nerve
lateral margin of rectus sheath
intercostal arteries
lumbar arteries
deep circumflex iliac artery
position of deep inguinal ring
inferior epigastric artery

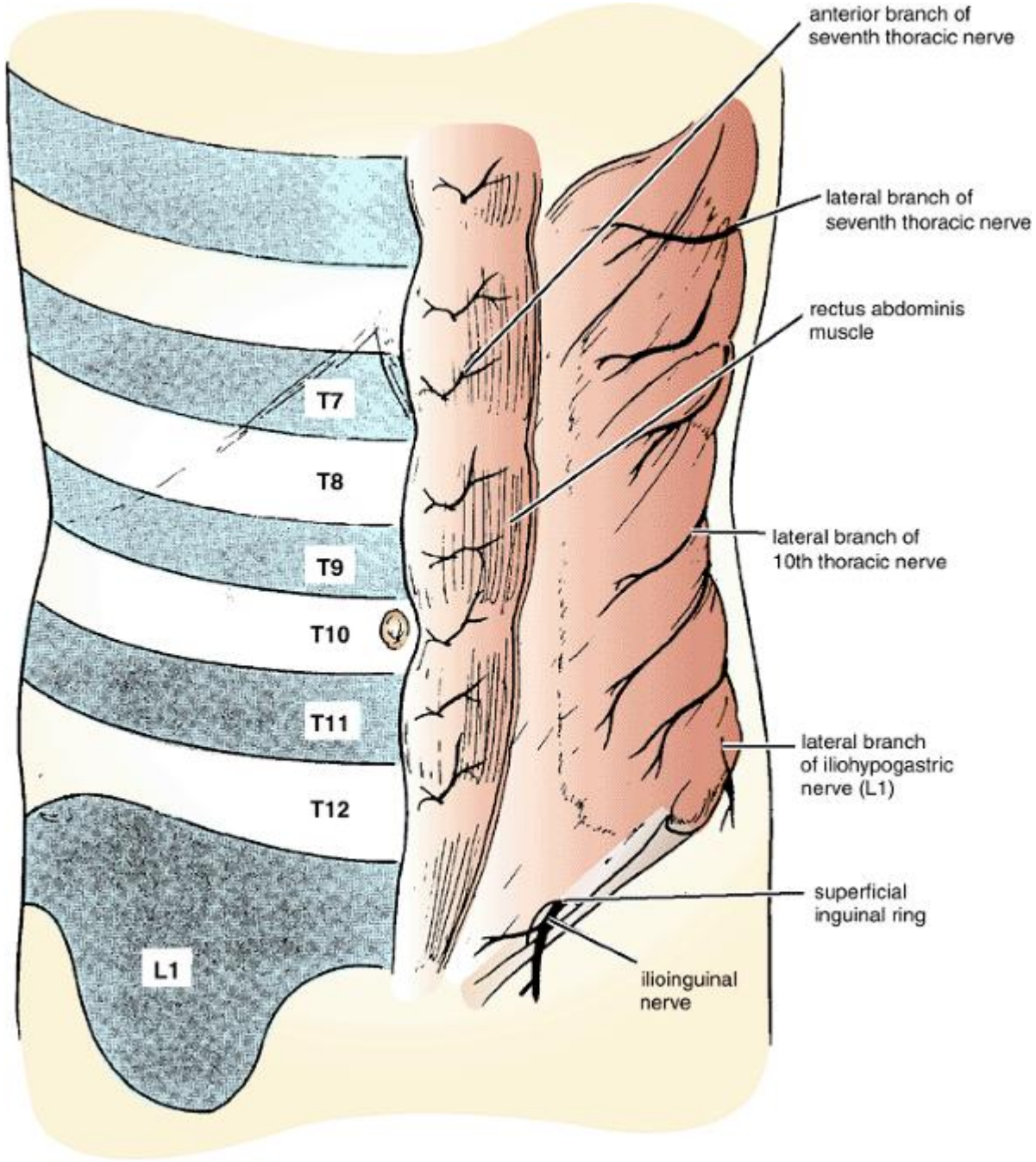
anterior branch of seventh thoracic nerve
lateral branch of seventh thoracic nerve
rectus abdominis muscle
T7
T8
T9
T10
T11
T12
L1
lateral branch of 10th thoracic nerve
lateral branch of iliohypogastric nerve (L1)
superficial inguinal ring
ilioinguinal nerve

Dermatomes Of Anterior Abdominal Wall:

T 7: Epigastrium over xiphoid process

T 10: Includes umbilicus

L 1: Just above inguinal ligament and symphysis pubis

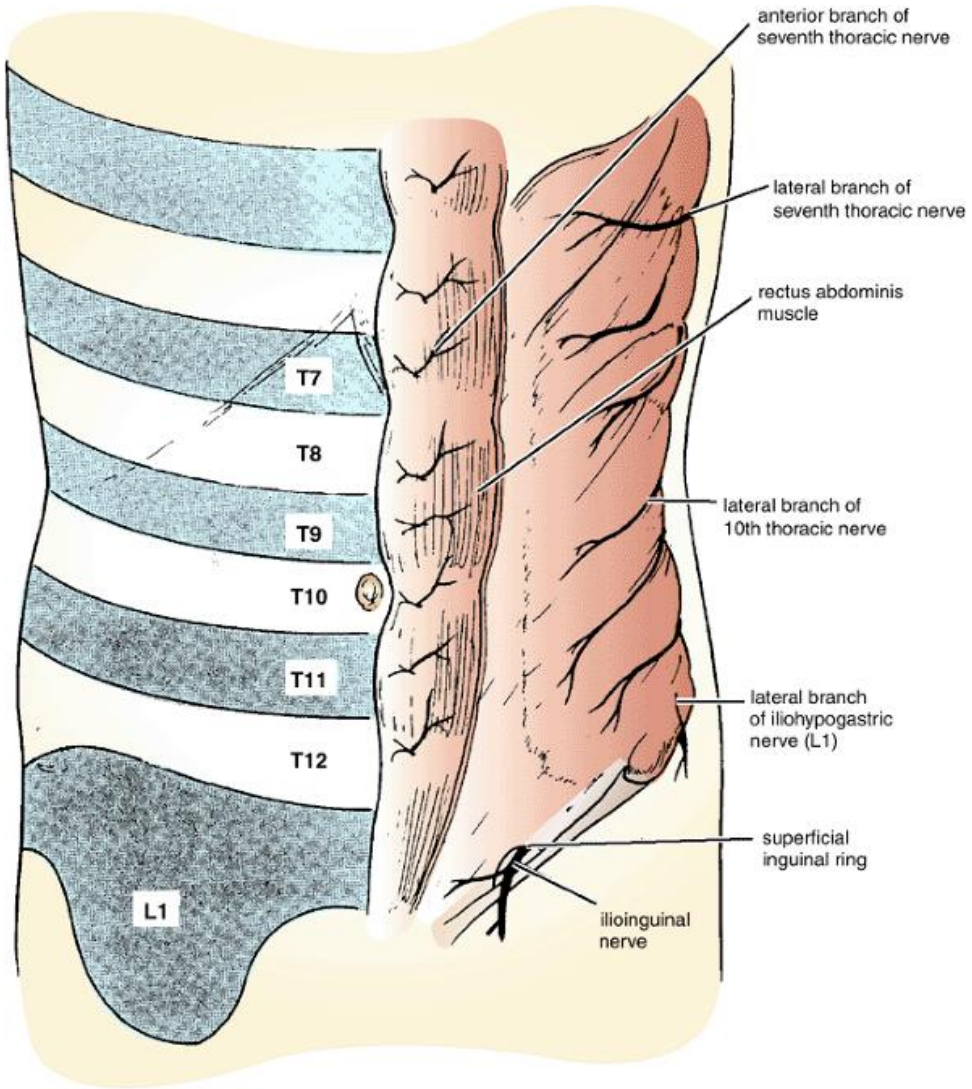

ARTERIAL SUPPLY

Skin near midline:

1. Superior epigastric artery (internal thoracic)
2. Inferior epigastric artery (external iliac)
3. Superficial epigastric artery (femoral)
4. Lateral thoracic artery (axillary)

Skin of flanks:

1. Posterior intercostal arteries (descending thoracic aorta)
2. Lumbar arteries (abdominal aorta)
3. Deep circumflex iliac artery (external iliac)
4. Superficial circumflex iliac artery (femoral).

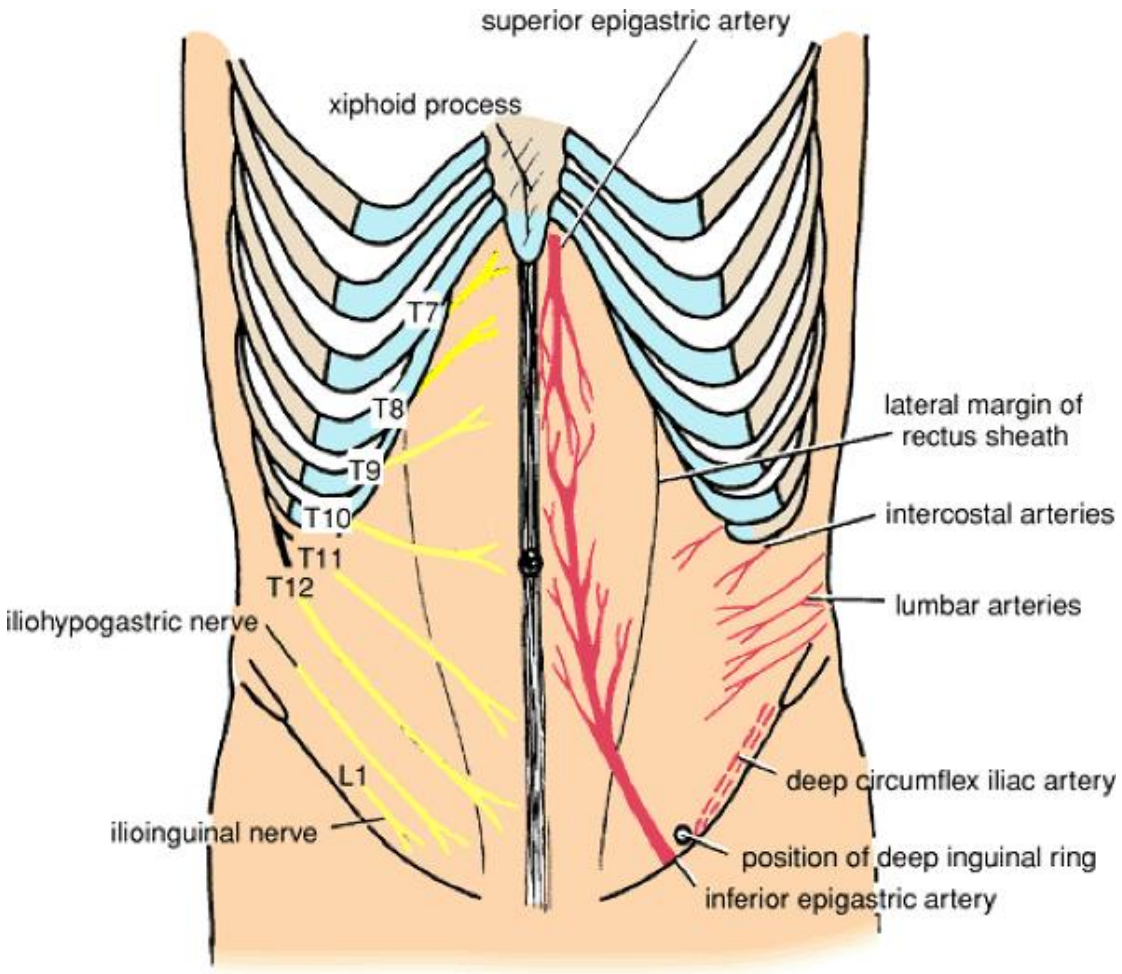

VENOUS DRAINAGE

1. Network of veins:

❖Radiate out from umbilicus.

❖Drained above into axillary vein via lateral thoracic vein.

❖Drained below into femoral vein via superficial epigastric and great saphenous veins.

2. Few small veins (paraumbilical veins):

❖Connect the network through the umbilicus and along ligamentum teres to portal vein.

❖Form important portal-systemic venous anastomosis.

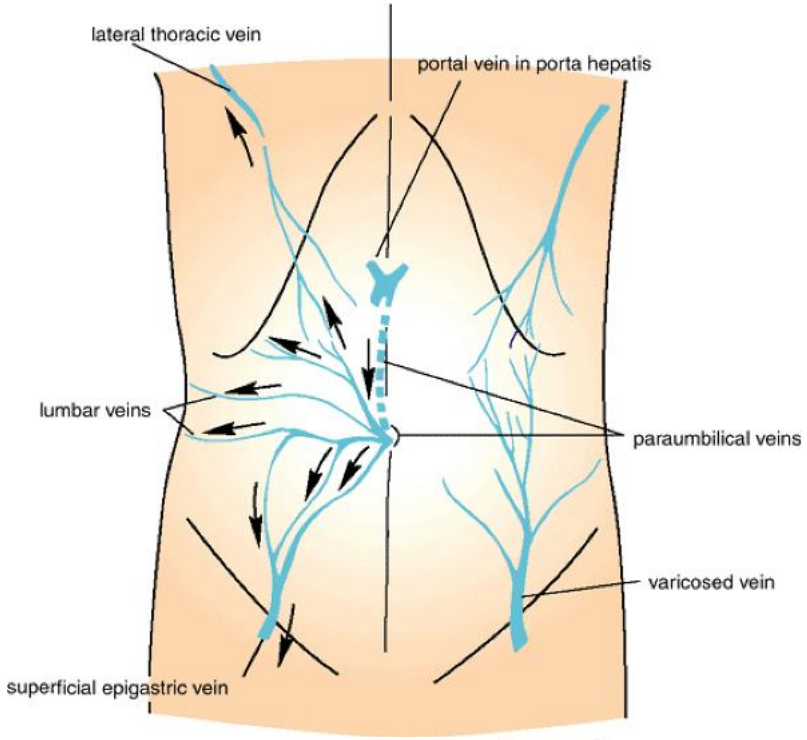

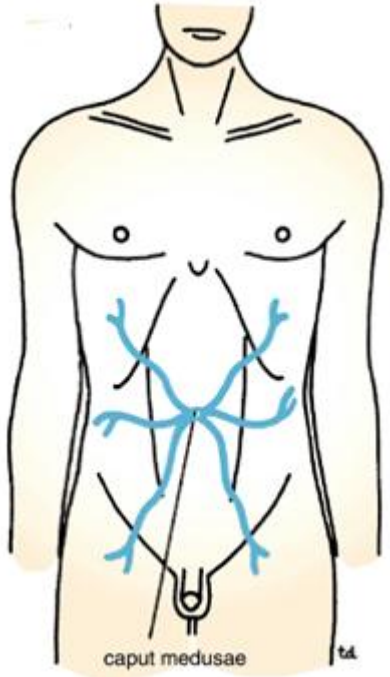

LYMPH DRAINAGE
(cutaneous lymph vessels)

1. **Above level of umbilicus:**
   Anterior axillary lymph nodes
2. **Below level of umbilicus:**
   Superficial inguinal lymph nodes

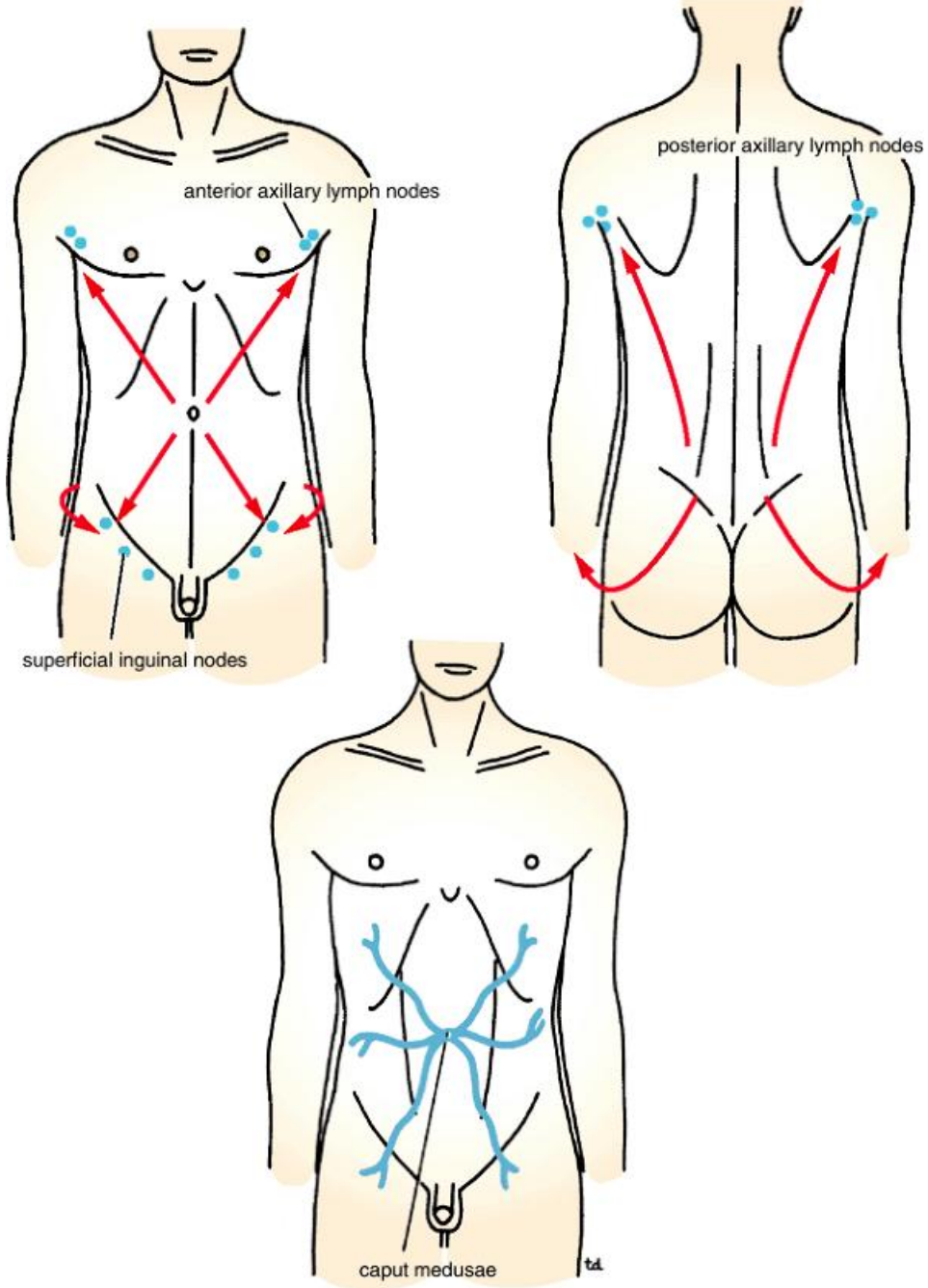

DEEP LYMPH VESSELS:

Follow the arteries

Drain into:

- Internal thoracic lymph nodes
- External iliac lymph nodes
- Para-aortic (lumbar) lymph nodes
- Posterior mediastinal lymph nodes

SUPERFICIAL FASCIA

1. Superficial fatty layer:

- ❖Continues with superficial fat over rest of the body.
- ❖May be extremely thick, 3 inches or more in obese patients.

❖Called: ***Fascia of Camper.***

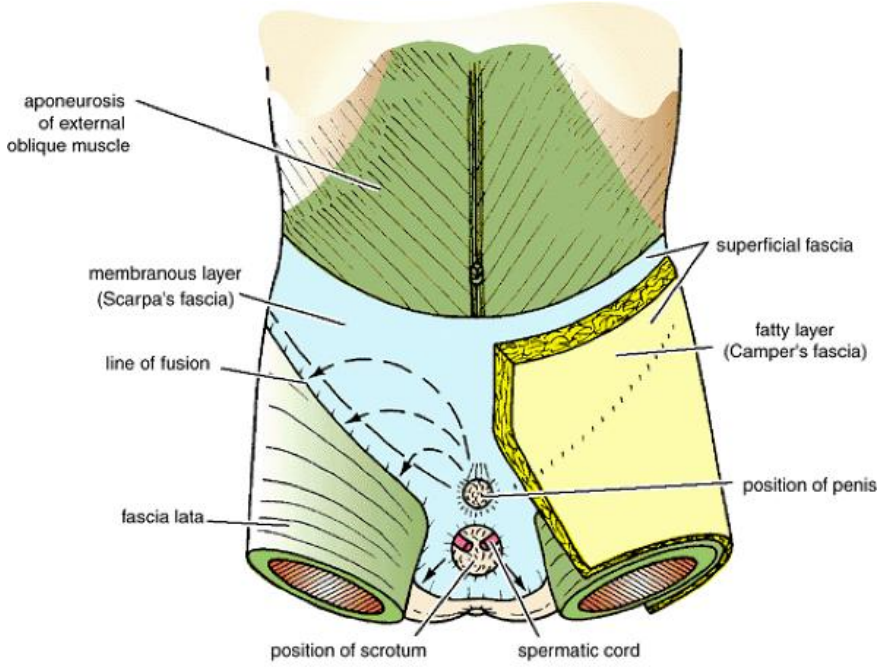

In scrotum: No fat, represented by thin layer of smooth muscle ***(dartos muscle).***

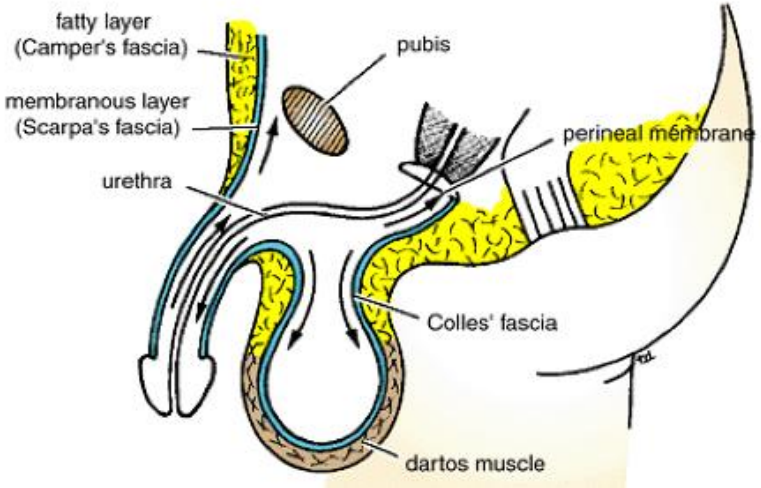

Deep membranous layer:

❖Thin and fades out laterally and above, where continues with superficial fascia of the back and thorax, respectively.

❖**Inferiorly:** Passes onto front of thigh and fuses with deep fascia one fingerbreadth below inguinal ligament.

❖**In midline inferiorly**: Not attached to pubis but forms tubular sheath for penis (clitoris).

❖**Below in perineum**: Enters wall of scrotum (labia majora) and attached on each side of margins of pubic arch.

❖**Posteriorly**: Fuses with perineal body and posterior margin of perineal membrane

❖Called ***Scarpa's facia.***

In perineum: Persists as a separate layer (***Colles' fascia).***

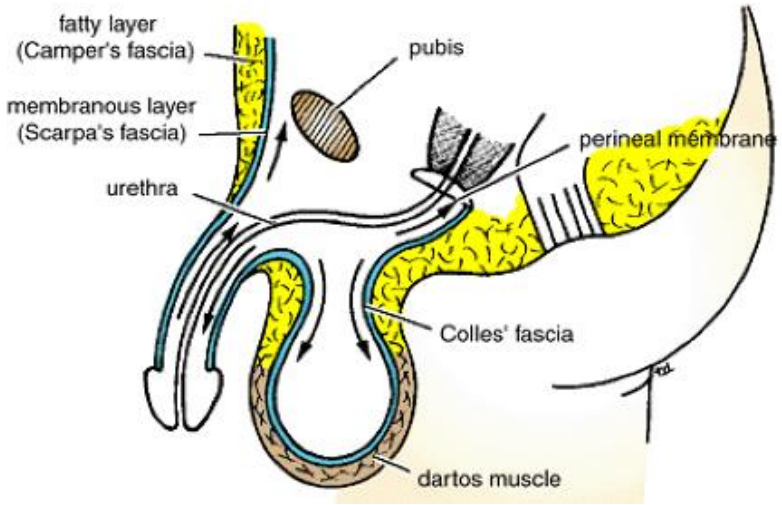

Muscles of anterolateral abdominal wall:

1. External oblique
2. Internal oblique
3. Transversus abdominis
4. Rectus abdominis
5. Pyramidalis

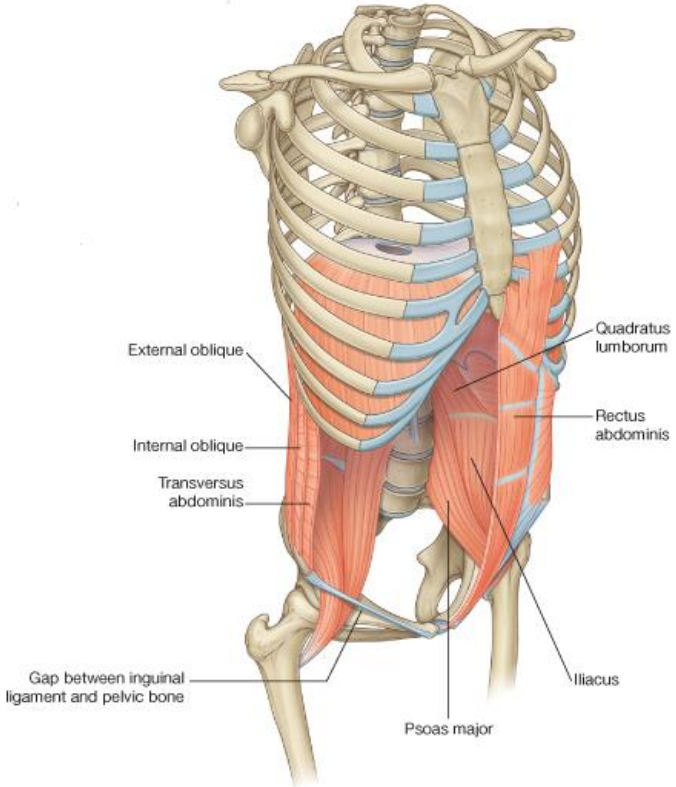

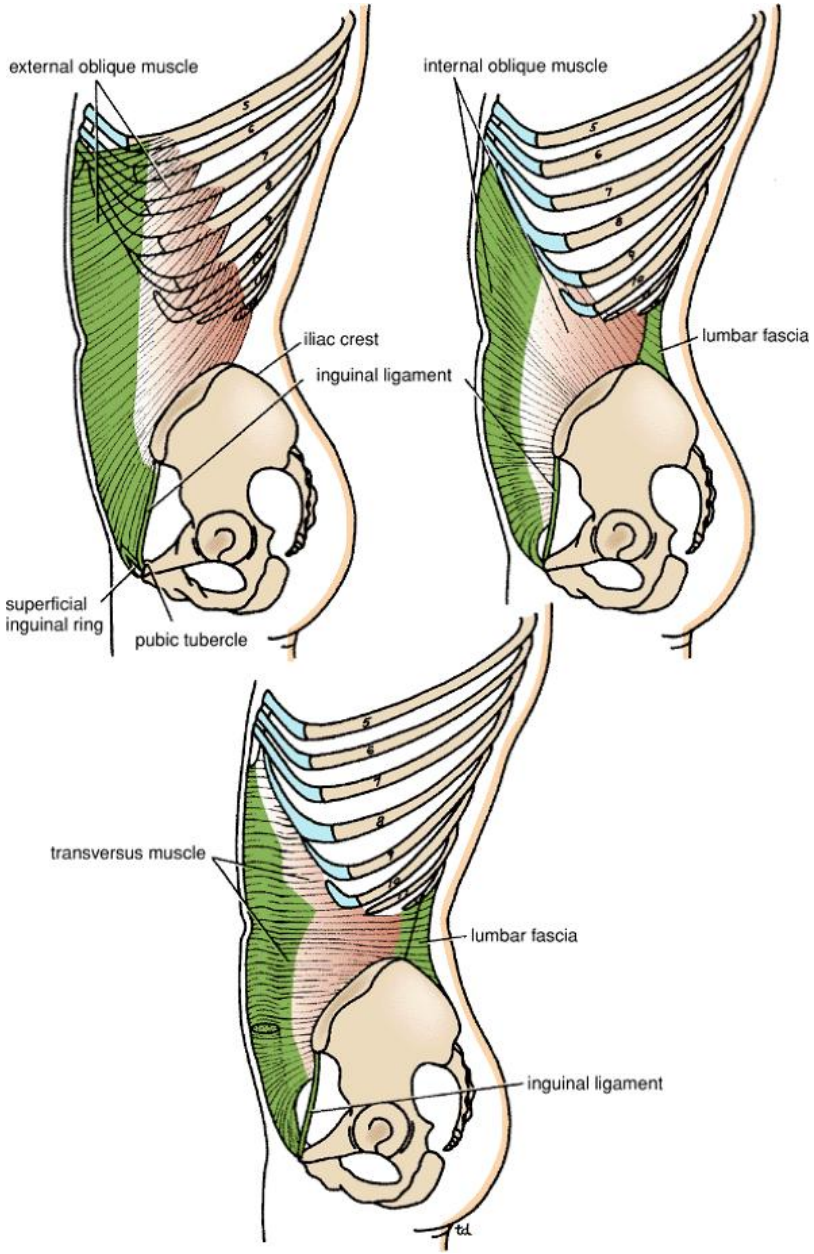

EXTERNAL ABDOMINAL OBLIQUE

Broad thin muscular sheet

Its fibres run downward and forward

Origin: Outer surfaces of lower 8 ribs

Insertion:

1. Xiphoid process
2. Linea alba
3. Pubic crest
4. Pubic tubercle
5. Anterior half of iliac crest

Nerve supply:

- Lower 6 thoracic nerves
- Iliohypogastric nerve (L 1)
- Ilioinguinal nerve (L 1)

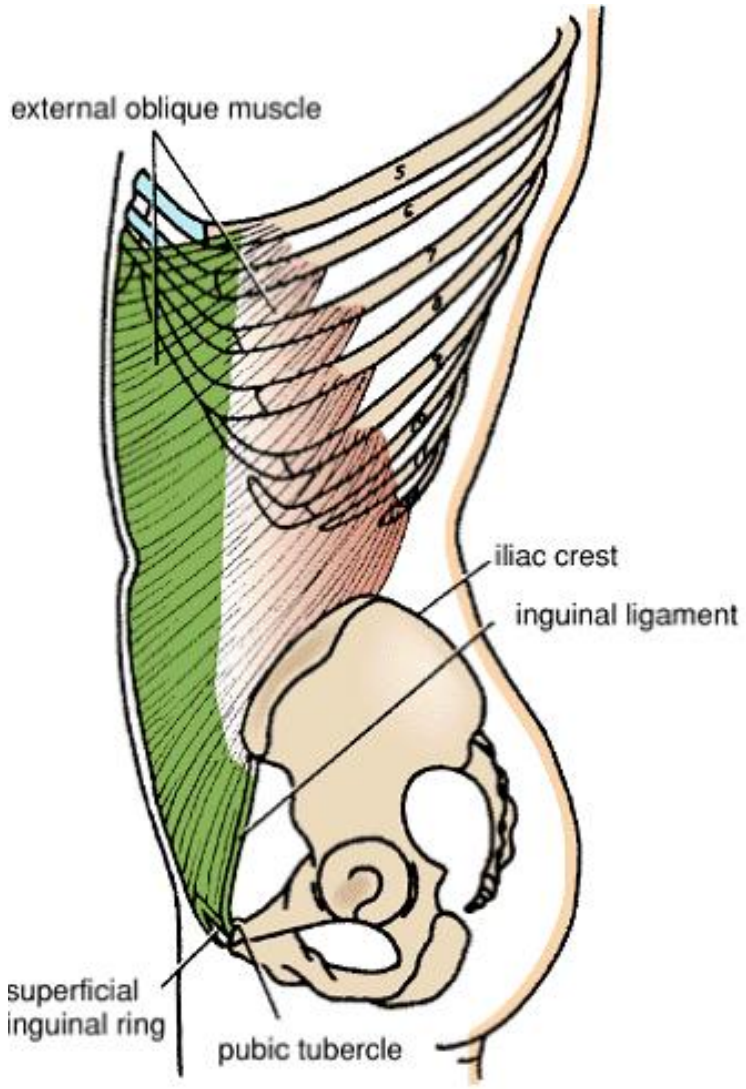

Action of external oblique muscle:

1. Supports abdominal contents
2. Compresses abdominal contents
3. Assists in flexion and rotation of trunk
4. Assists in forced expiration, micturition, defecation, parturition and vomiting

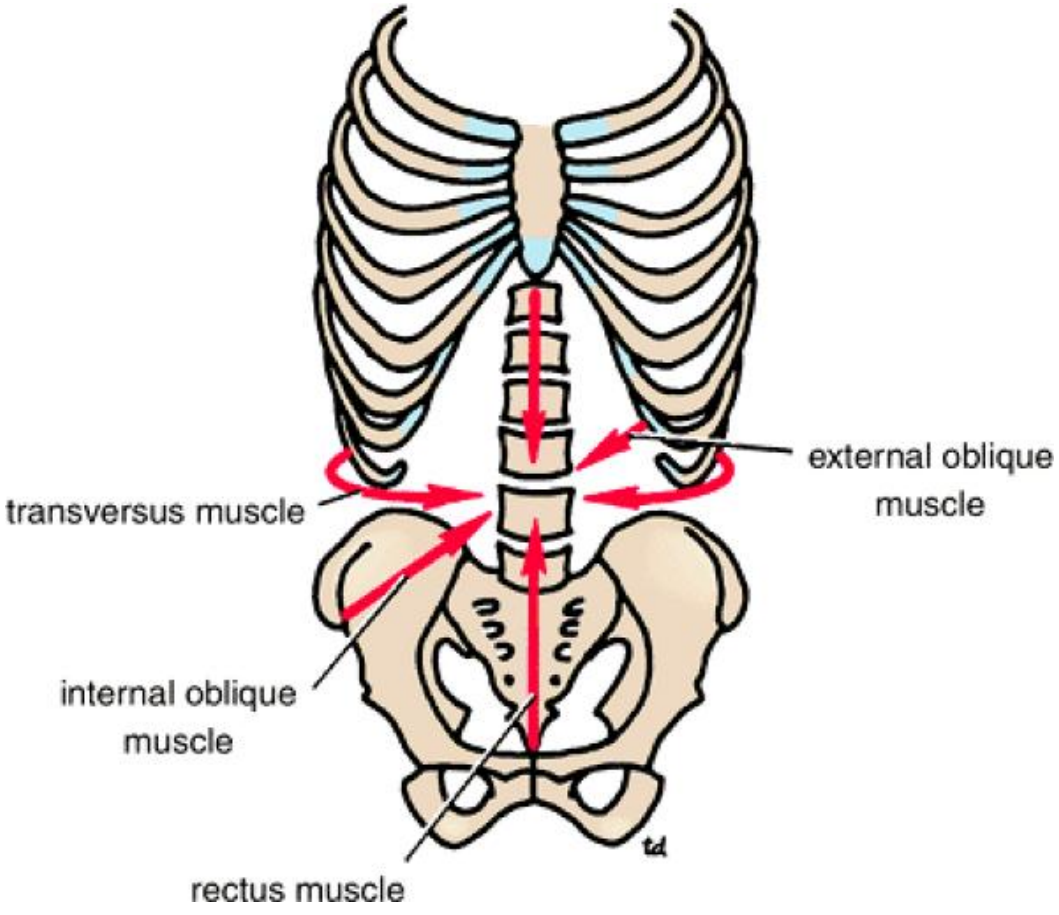

INGUINAL LIGAMENT:

- ❖Lower border of aponeurosis of external oblique folded backward on itself.
- ❖Between anterior superior iliac spine and pubic tubercle.
- ❖Lateral part of its posterior edge gives origin to part of internal oblique and transversus abdominis muscles.
- ❖Fascia lata of thigh attached to its inferior rounded border.

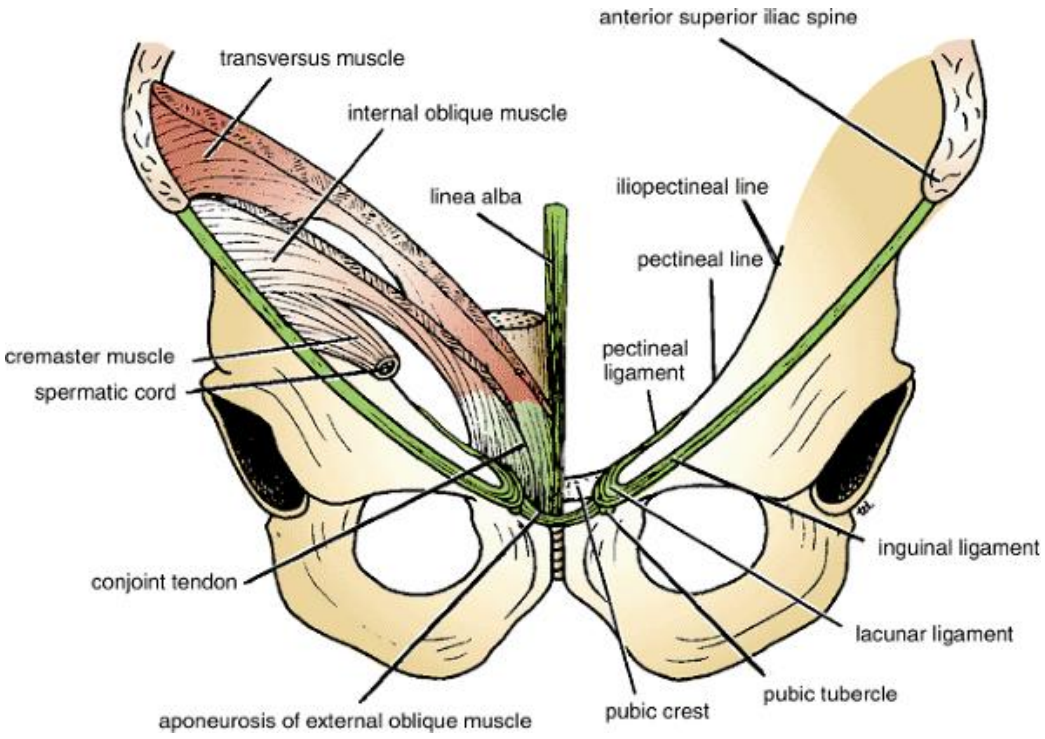

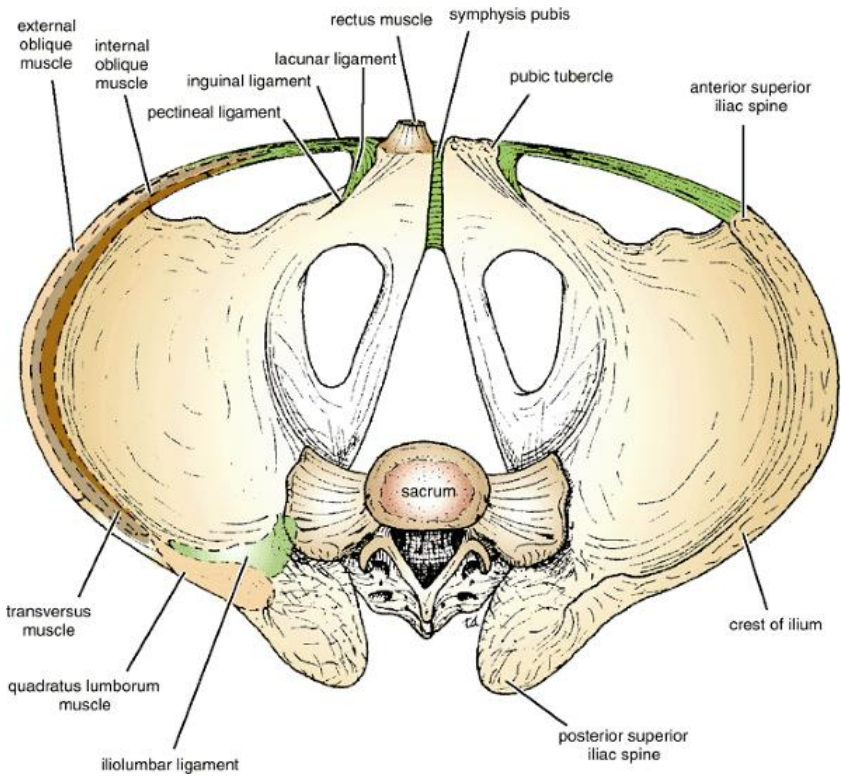

INTERNAL OBLIQUE

- Broad thin muscular sheet, deep to external oblique muscle of the abdomen.
- Its fibres run upward and forward.

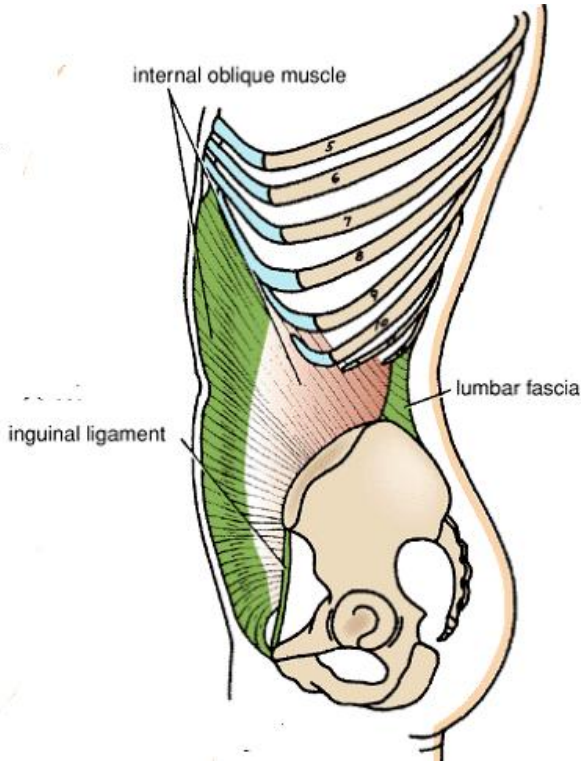

Origin:

1. Lumbar fascia
2. Anterior two-thirds of iliac crest
3. Lateral two-thirds of inguinal ligament

Insertion:

1. Lower borders of lower 3 ribs and their costal cartilages.
2. Xiphoid process
3. Linea alba
4. Symphysis pubis
5. Pubic crest
6. Pectineal line

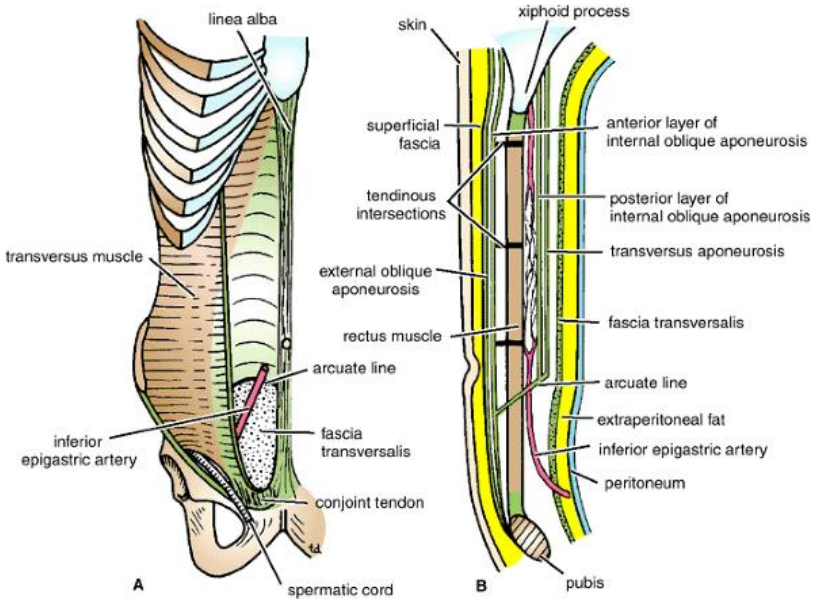

Nerve supply of internal oblique:

- Lower 6 thoracic nerves
- Iliohypogastric nerve (L 1)
- Ilioinguinal nerve (L 1)

Action of internal oblique muscle :

- Supports abdominal contents
- Compresses abdominal contents
- Assists in flexion and rotation of trunk.
- Assists in forced expiration, micturition, defecation, parturition and vomiting.

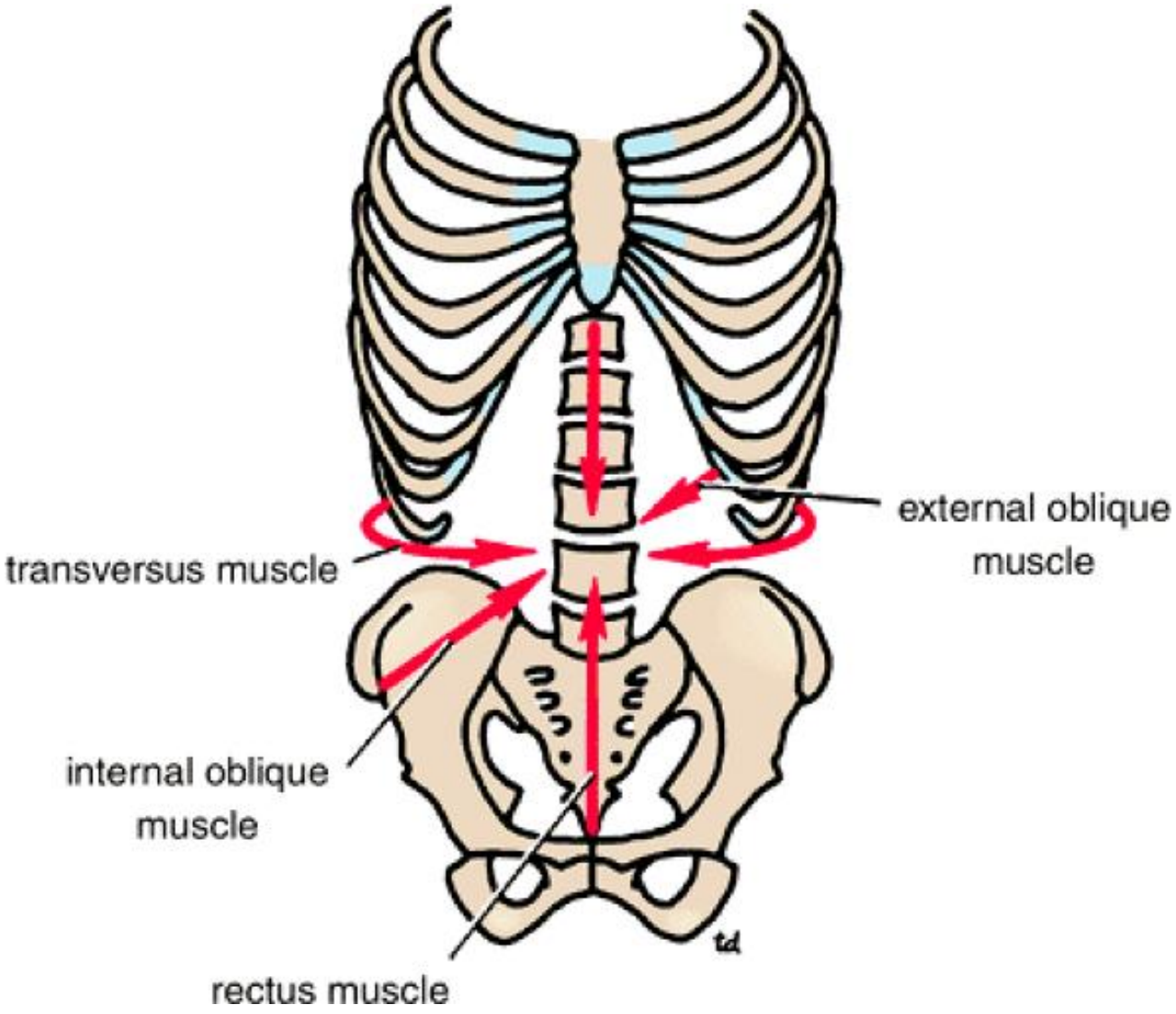

TRANSVERSUS ABDOMINIS

Origin:

1. Deep surface of lower 6 costal cartilages (interdigitating with diaphragm).
2. Lumbar fascia
3. Anterior two-thirds of iliac crest
4. Lateral third of inguinal ligament

Insertion of transversus abdominis:

1. Xiphoid process
2. Linea alba
3. Symphysis pubis

Nerve supply:

- Lower 6 thoracic nerves
- Iliohypogastric nerve (L 1)
- Ilioinguinal nerve (L 1)

Action: Compression of abdominal contents

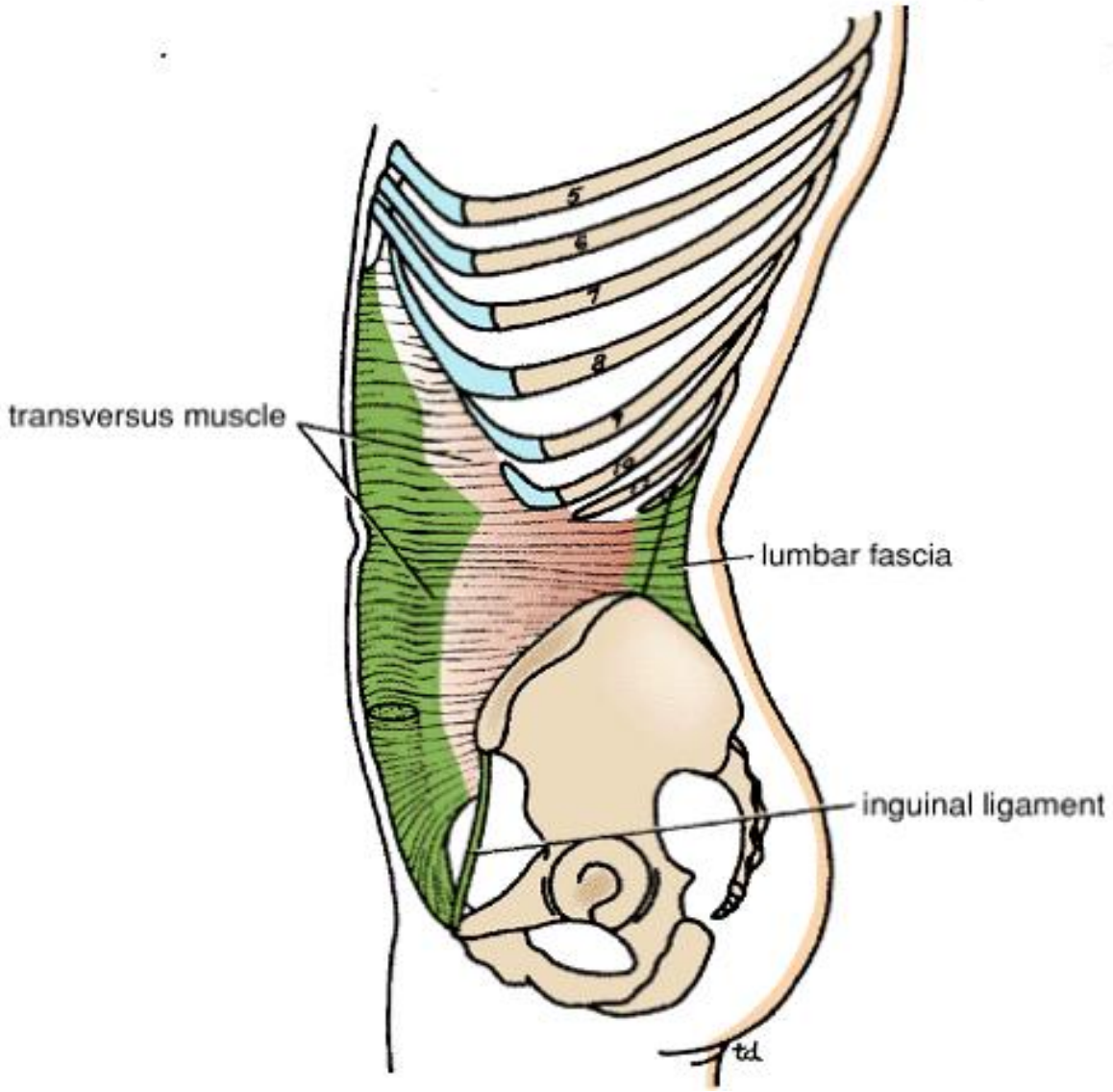

RECTUS ABDOMINIS

- Long strap muscle, broader above
- Extends along whole length of ant. abdominal wall.
- Lies close to midline, separated from its fellow by linea alba.
- Divided into segments by transverse tendinous intersections.

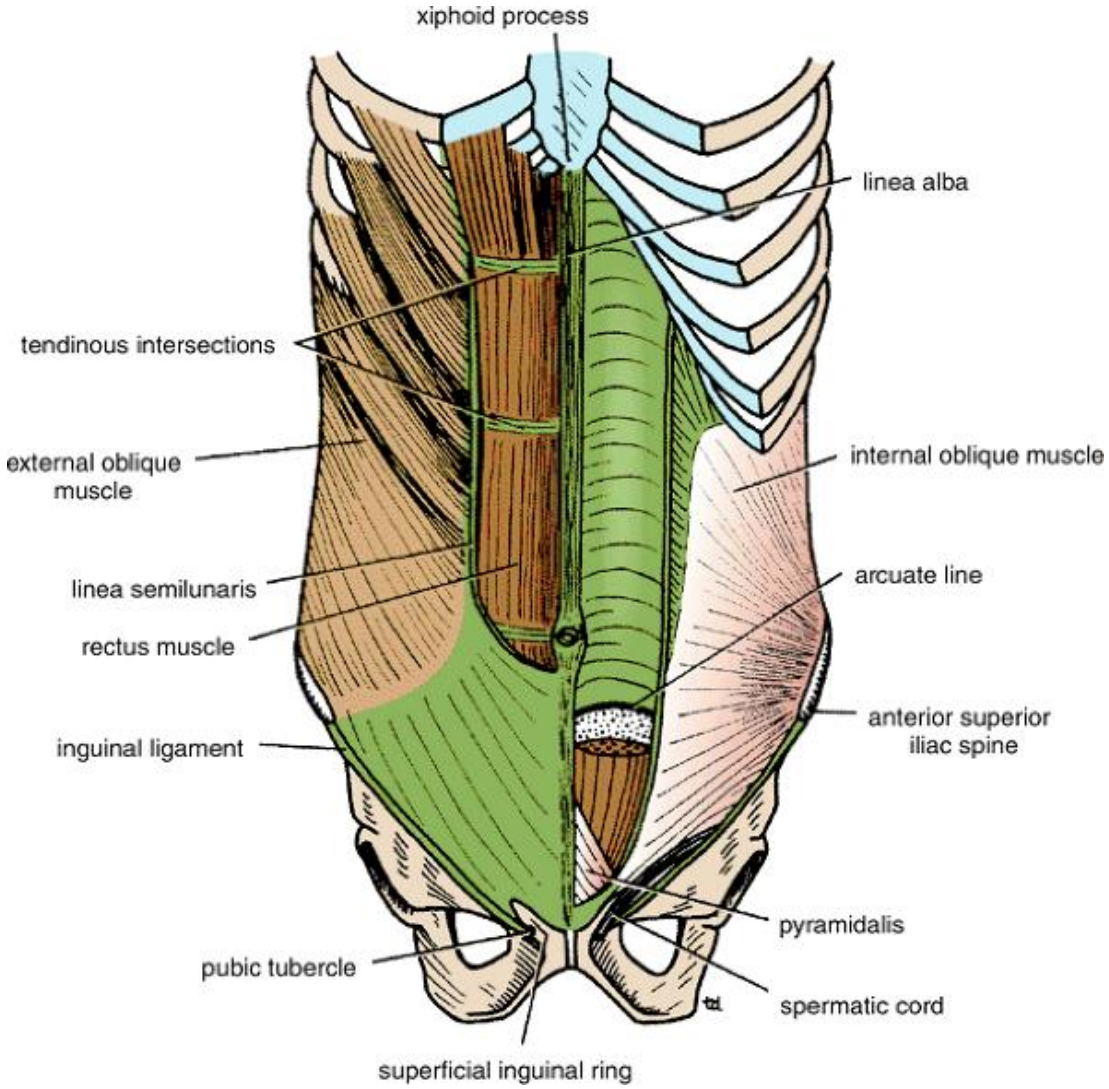

Usually 3 intersections:-

1. At level of xiphoid process
2. At level of umbilicus
3. Halfway between these two

Origin of rectus abdominis:

(2 heads):

1. Front of symphysis pubis
2. Pubic crest

Insertion:

- 5th, 6th and 7th costal cartilages
- Xiphoid process

Nerve supply:

Lower 6 thoracic nerves

Action of rectus abdominis:

- Compression of abdominal contents.
- Flexion of vertebral column
- Accessory muscle of expiration

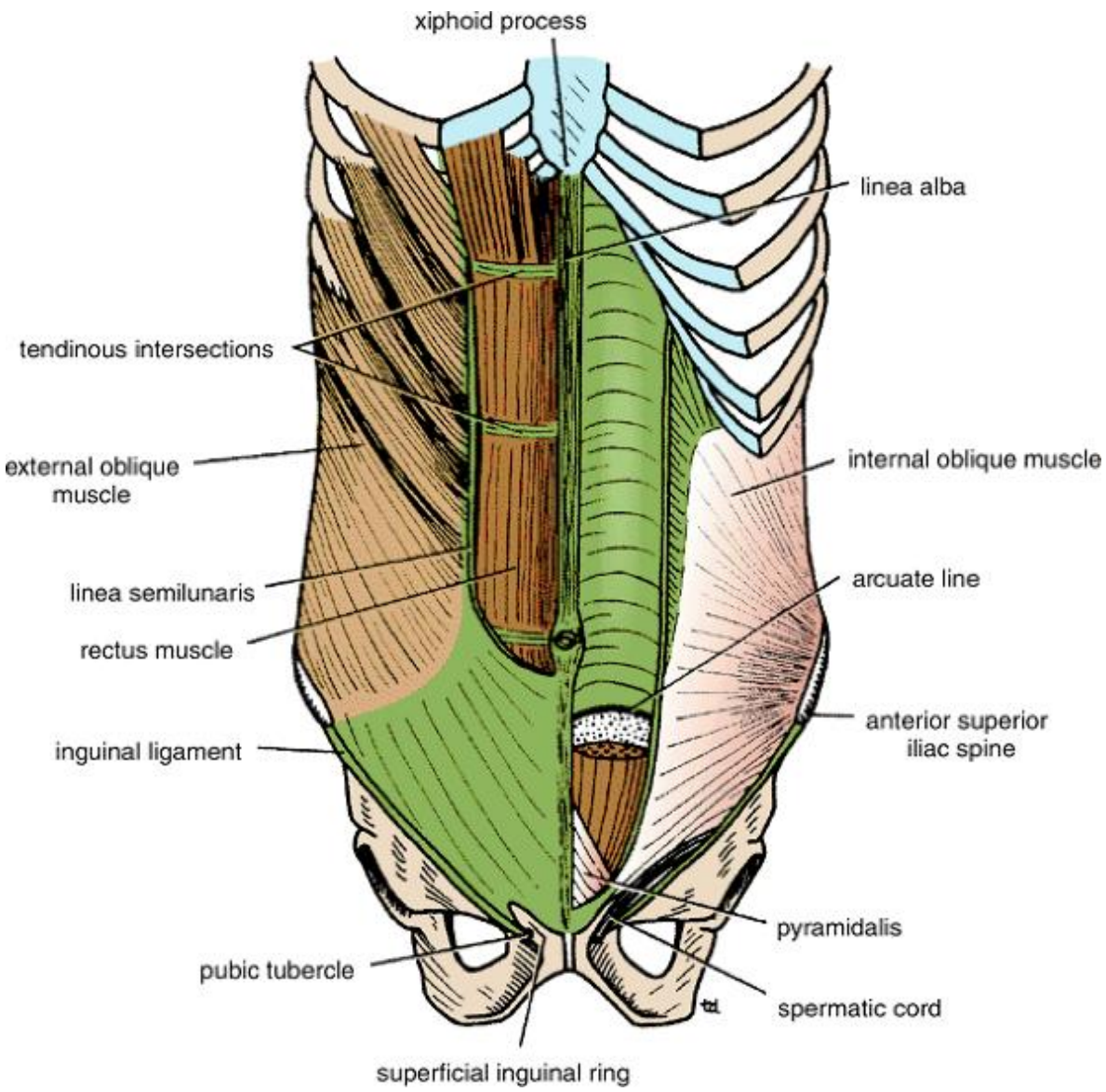

PYRAMIDALIS

- ❖Often absent
- ❖In front of rectus abdominis

Origin: Anterior surface of pubis

Insertion: Linea alba

Nerve supply: Subcostal nerve

Action: Tenses the linea alba

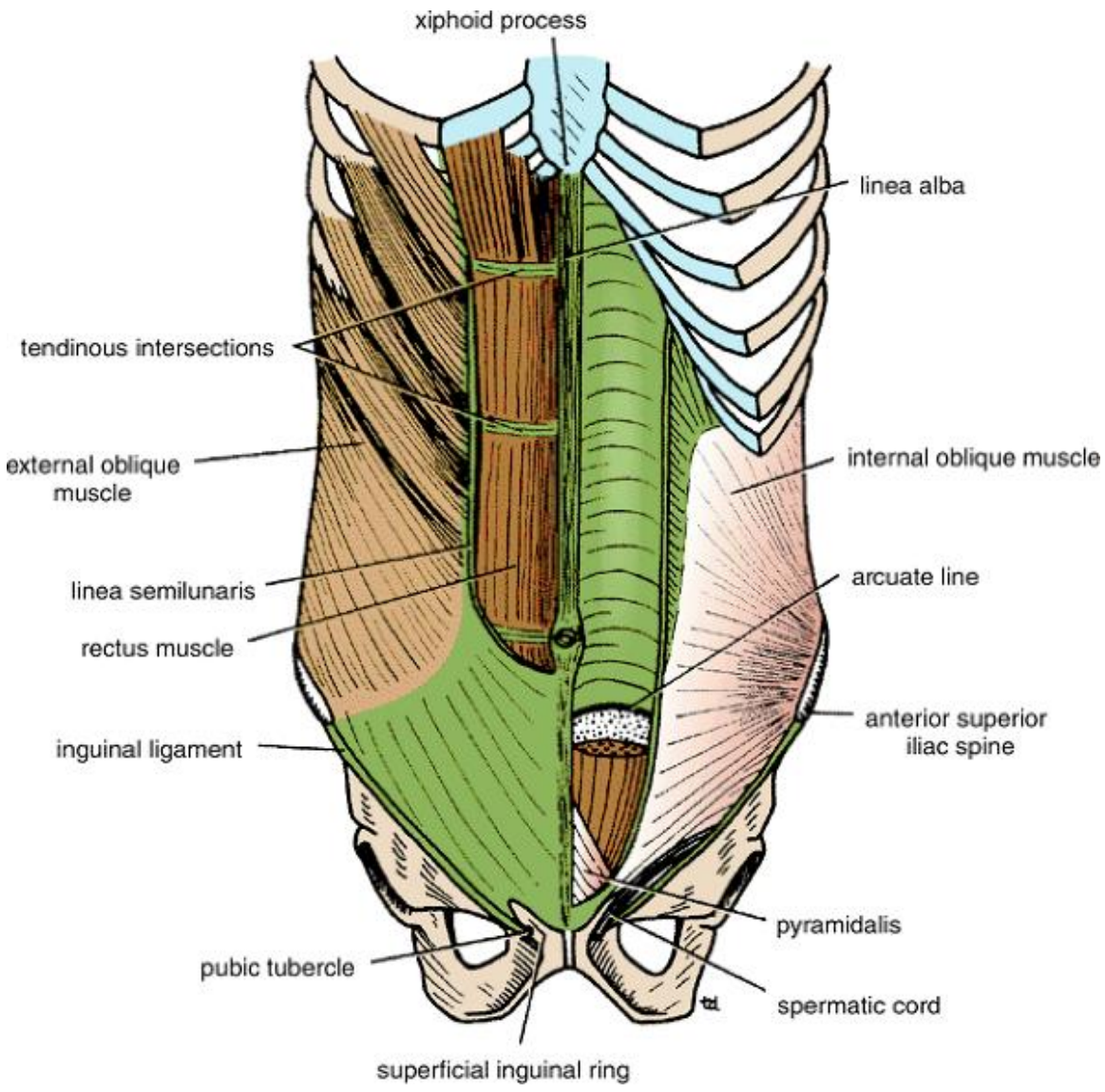

CREMASTER

Origin: (Lateral and medial parts):

- **Lateral part: Middle of upper surface of inguinal ligament as part of internal oblique and descends along lateral side of spermatic cord to scrotum.**
- **Medial part: Pubic tubercle and descends along medial side of spermatic cord.**

Insertion: Pubic tubercle:

In scrotum: 2 parts form loops and bundles around the cord and attached to its fascial coverings and tunica vaginalis of testis.

Nerve supply: Genital branch of genitofemoral nerve.

Action: (cremaster means elevator)

Elevation of testis towards superficial inguinal ring.

RECTUS SHEATH

- Long fibrous sheath
- Formed mainly by aponeuroses of the 3 lateral abdominal muscles

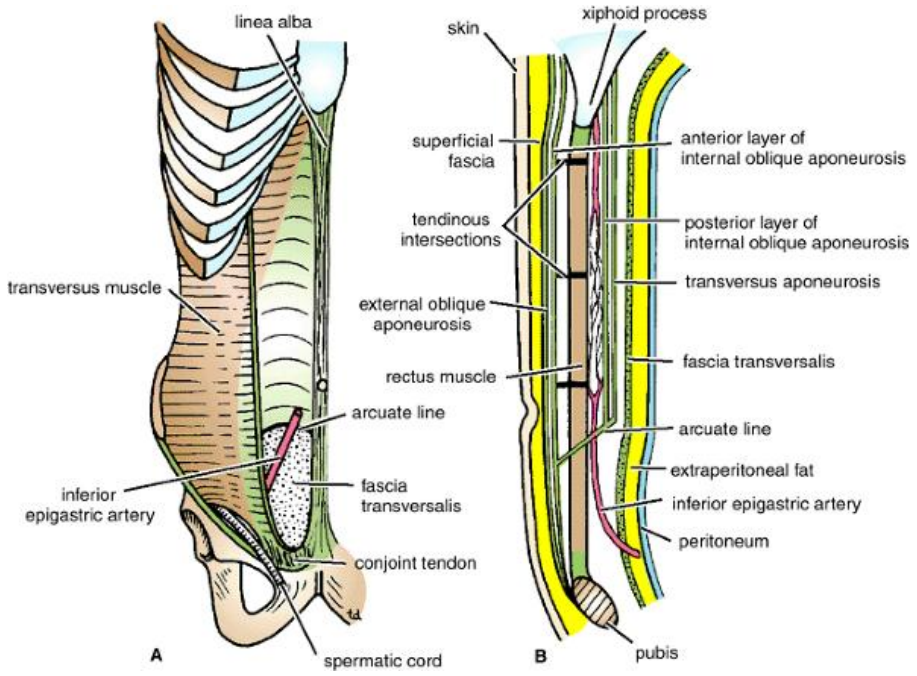

Contents Of Rectus Sheath:

1. Rectus abdominis muscle
2. Pyramidalis muscle (if present)
3. Anterior rami of lower 6 thoracic nerves (lower 5 intercostal and subcostal nerves)
4. Superior epigastric vessels
5. Inferior epigastric vessels
6. Lymph vessels

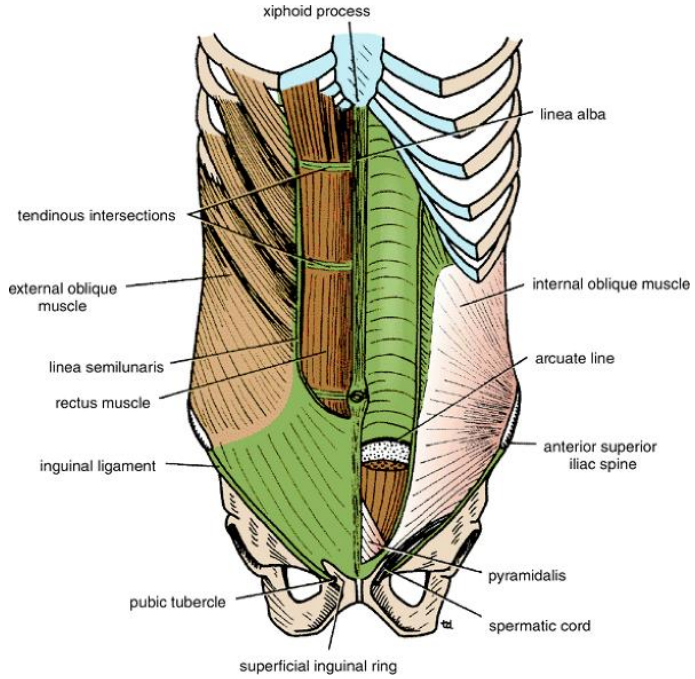

WALLS OF RECTUS SHEATH:

1. **Above the costal margin:**
   a. **Anterior wall:** Aponeurosis of external oblique
   b. **Posterior wall:** Thoracic wall (5th, 6th and 7th costal cartilages and intercostal spaces)

2. **Between costal margin and level of ant. superior iliac spine:**
   a. **Anterior wall:**
   - Aponeurosis of external oblique
   - Anterior layer of internal oblique aponeurosis

   b. **Posterior wall:**
   - Posterior layer of internal oblique aponeurosis
   - Transversus abdominis aponeurosis

3. **Between the level of ASIS and the pubis:**
   a. **Anterior wall:**

Aponeuroses of: external oblique, internal oblique and transversus abdominis

   b. **Posterior wall:** Absent (Fascia transversalis)

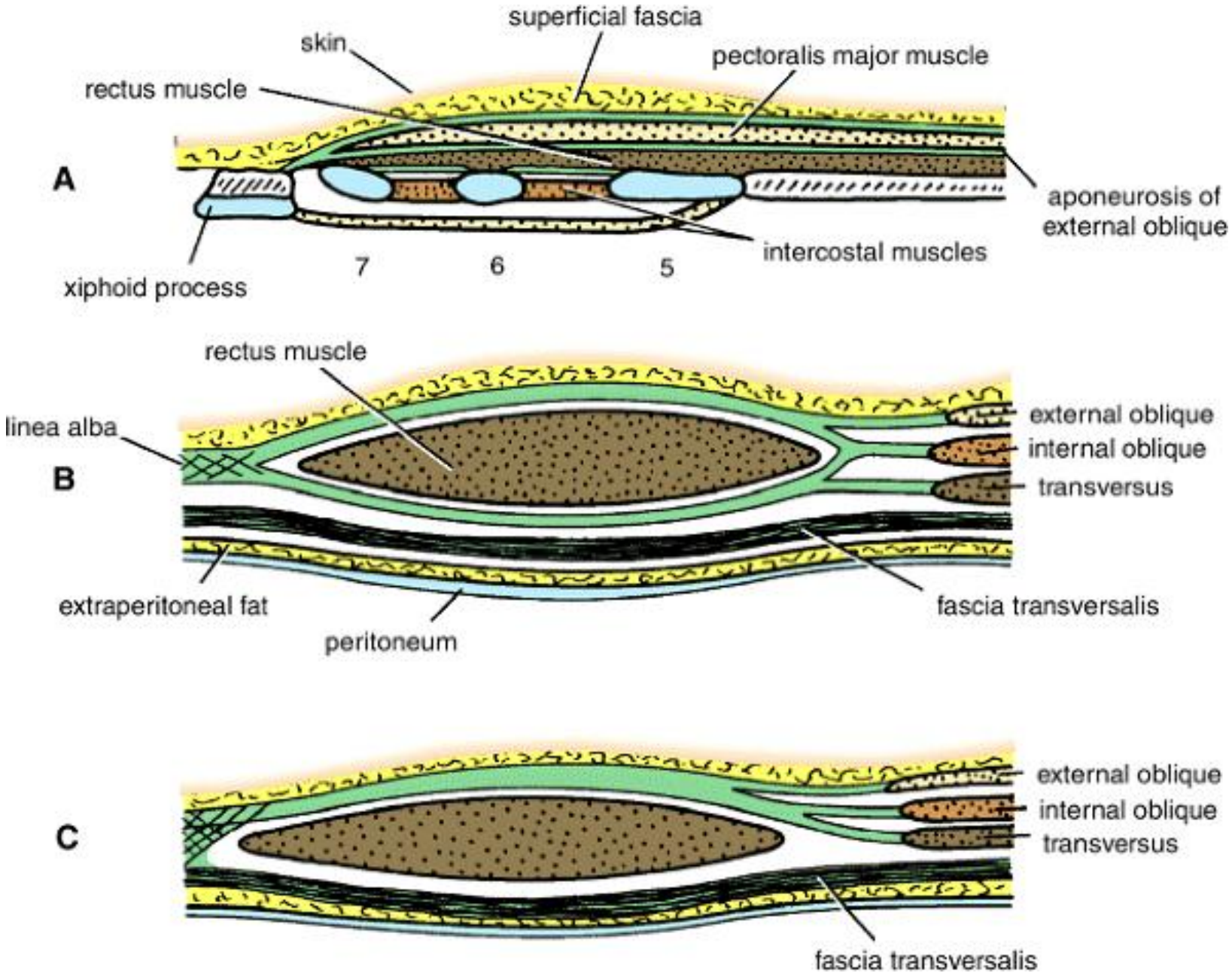
superficial fascia
skin
pectoralis major muscle
rectus muscle
A
aponeurosis of
external oblique
intercostal muscles
7
6
5
xiphoid process
rectus muscle
linea alba
external oblique
internal oblique
B
transversus
extraperitoneal fat
fascia transversalis
peritoneum
external oblique
internal oblique
C
transversus
fascia transversalis

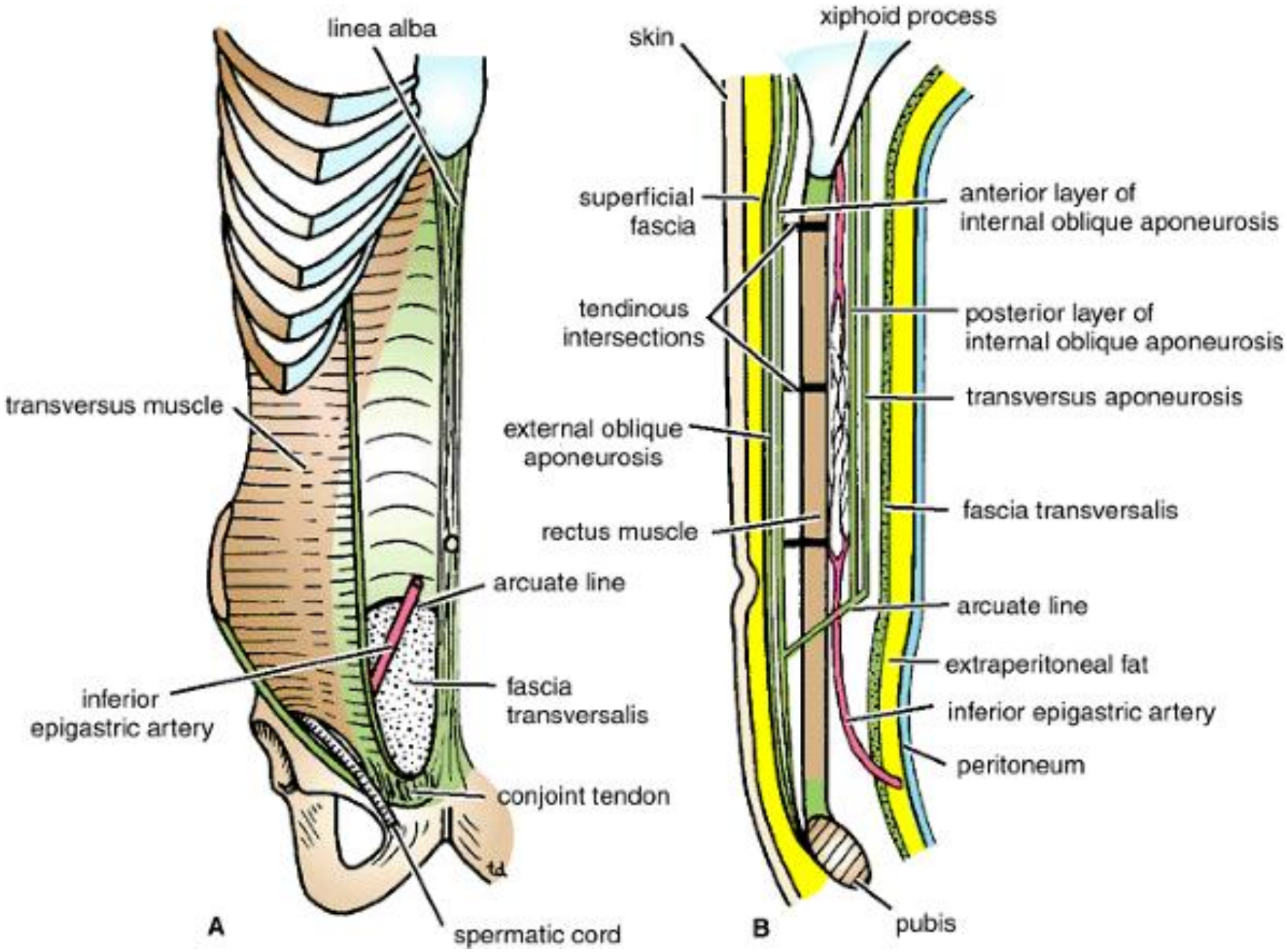
linea alba
transversus muscle
arcuate line
inferior
epigastric artery
fascia
transversalis
conjoint tendon
spermatic cord
A
skin
xiphoid process
superficial
fascia
anterior layer of
internal oblique aponeurosis
tendinous
intersections
posterior layer of
internal oblique aponeurosis
transversus aponeurosis
external oblique
aponeurosis
fascia transversalis
rectus muscle
arcuate line
extraperitoneal fat
inferior epigastric artery
peritoneum
pubis
B

INGUINAL CANAL

- ❖Oblique passage in lower part of anterior abdominal wall.
- ❖Parallel to and immediately above inguinal ligament.
- ❖Present in both sexes.
- ❖About 1.5 inches (4 Cm) long in the adult.

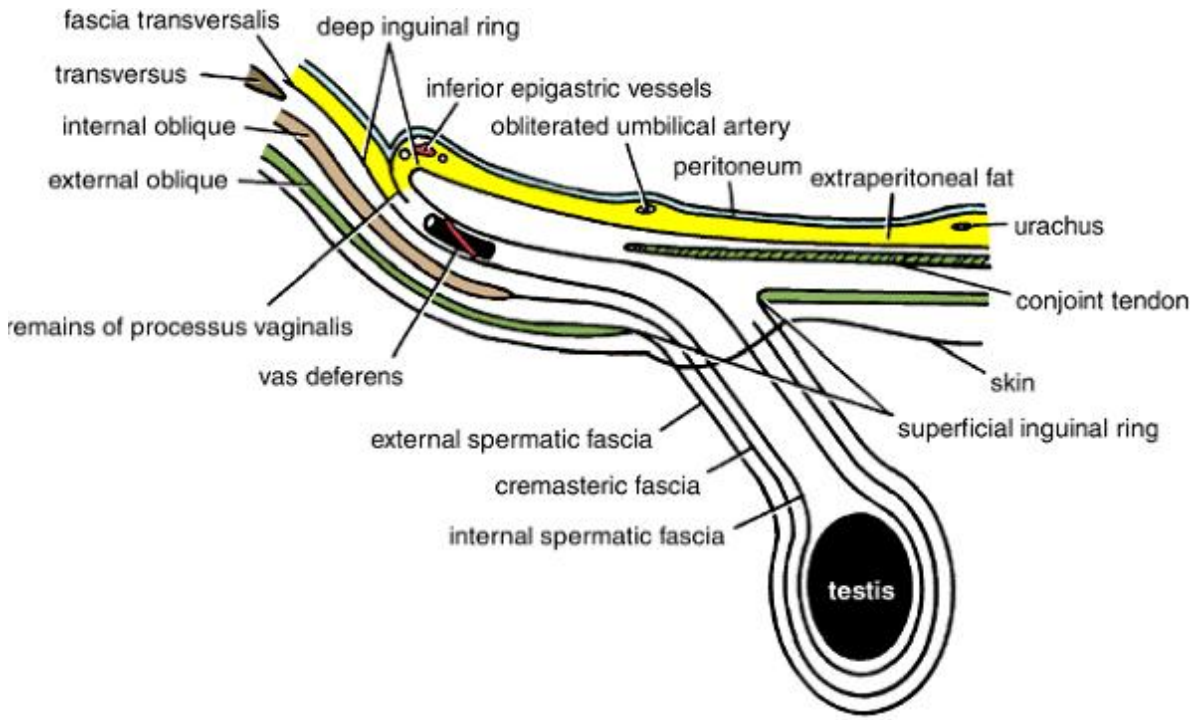

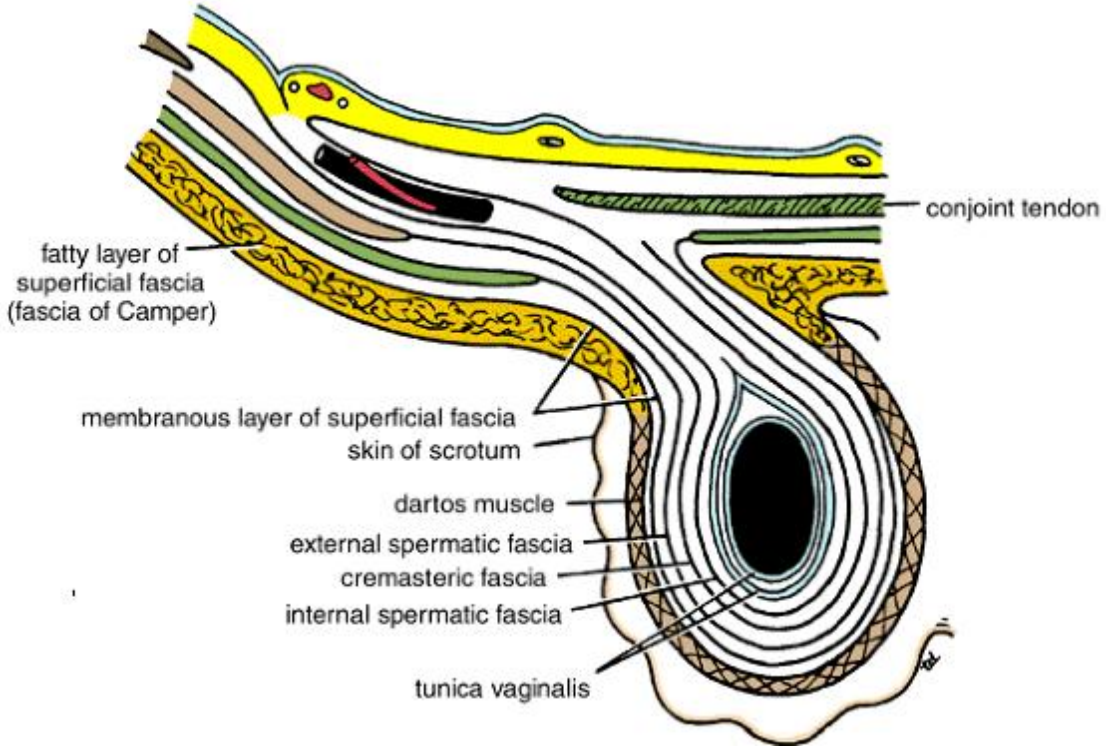

Extensions Of Inguinal Canal:

From deep inguinal ring to superficial inguinal ring.

Deep inguinal ring:

- Oval opening in fascia transversalis
- About ½ inch above inguinal ligament midway between anterior superior iliac spine and symphysis pubis.
- Related medially to inferior epigastric vessels (branches of external iliac vessels).

Superficial inguinal ring:

- Triangular-shaped defect in external oblique aponeurosis.
- Lies above and medial to pubic tubercle.

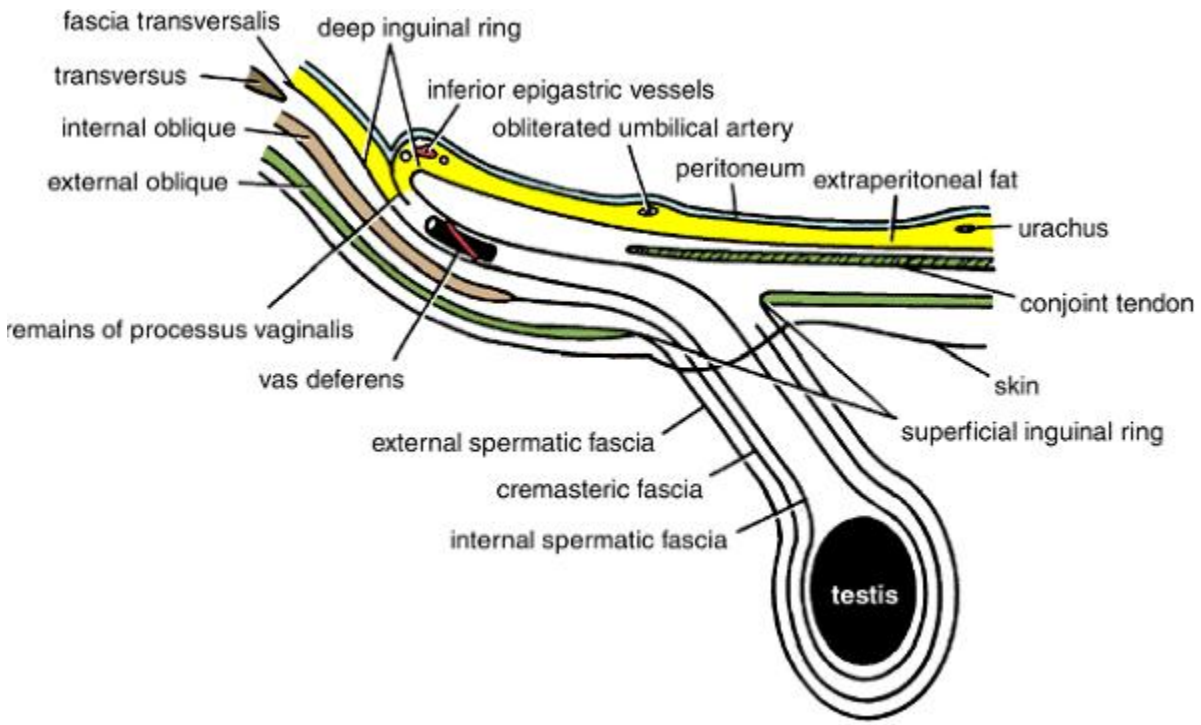

WALLS OF THE INGUINAL CANAL:

Anterior wall of inguinal canal:

- Aponeurosis of external oblique muscle along its whole length
- In its lateral third by fibres of origin of internal oblique.

Posterior wall of inguinal canal:

- Fascia transversalis along its entire length.
- Reinforced in its medial third by conjoint tendon (common tendon of insertion of internal oblique and transversus abdominis, attached to pubic crest and pectineal line).

Inferior wall (floor) of inguinal canal:

- Inguinal ligament and at its medial end lacunar ligament.

Superior wall of inguinal canal:

- Arching lowest fibres of internal oblique and transversus abdominis muscles.

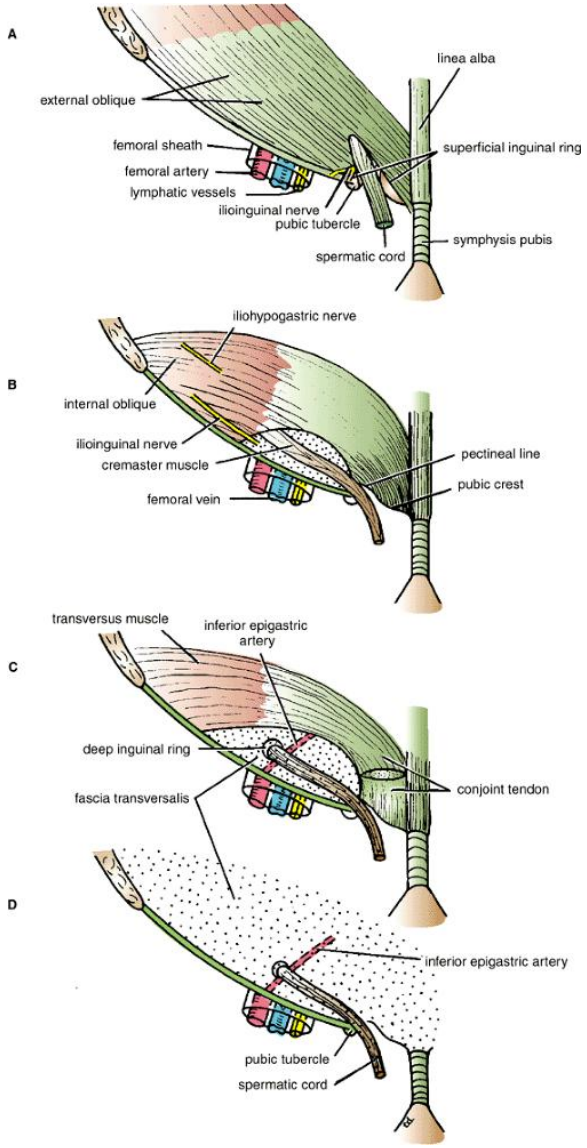

Contents Of Inguinal Canal:

In the male:

1. Spermatic cord
2. Ilioinguinal nerve

In the female:

1. Round ligament of the uterus
2. Ilioinguinal nerve

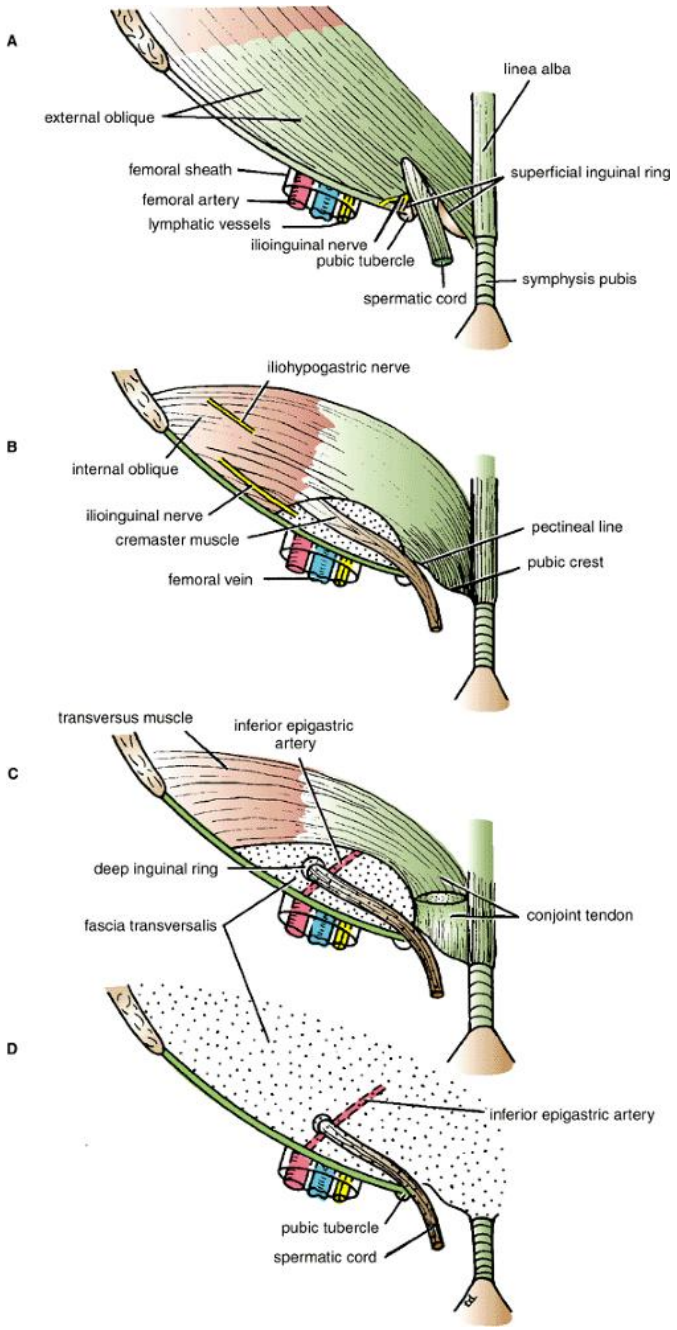

ABDOMINAL LINES AND PLANES

- Vertical lines and horizontal planes used to descripe of location of diseased structure or performing abdominal procedures

VERTICAL LINES:

- Each vertical line passes through midpoint between anterior superior iliac spine and symphysis pubis

TRANSPYLORIC PLANE (HORIZONTAL PLANE):

- Passes through tips of ninth costal cartilages on 2 sides
- Point where lateral margin of rectus abdominis crosses costal margin
- At level of body of 1st lumbar vertebra

Passes through:

1. Pylorus of stomach
2. Pyloroduodenal junction
3. Neck of the pancreas
4. Hila of the kidneys
5. Fundus of gall bladder

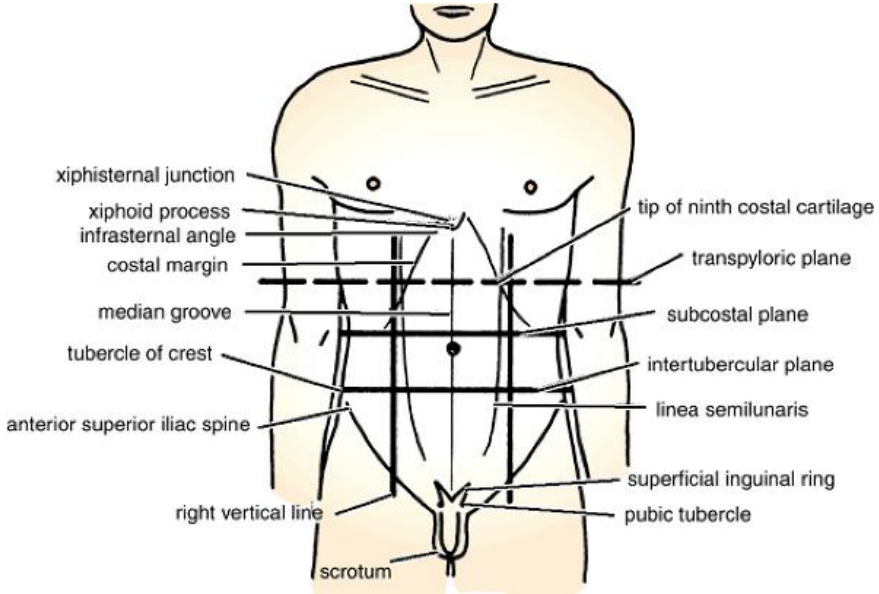

SUBCOSTAL PLANE:

- Horizontal plane joins lowest point of costal margin on each side (10th costal cartilage).
- At level of 3rd lumbar vertebra.

INTERCRISTAL PLANE:

- Passes across highest point on iliac crests
- Lies on level of body of 4th lumbar vertebra.

INTERTUBERCULAR PLANE:

- Horizontal plane joins iliac tubercles.
- At level of 5th lumbar vertebra.

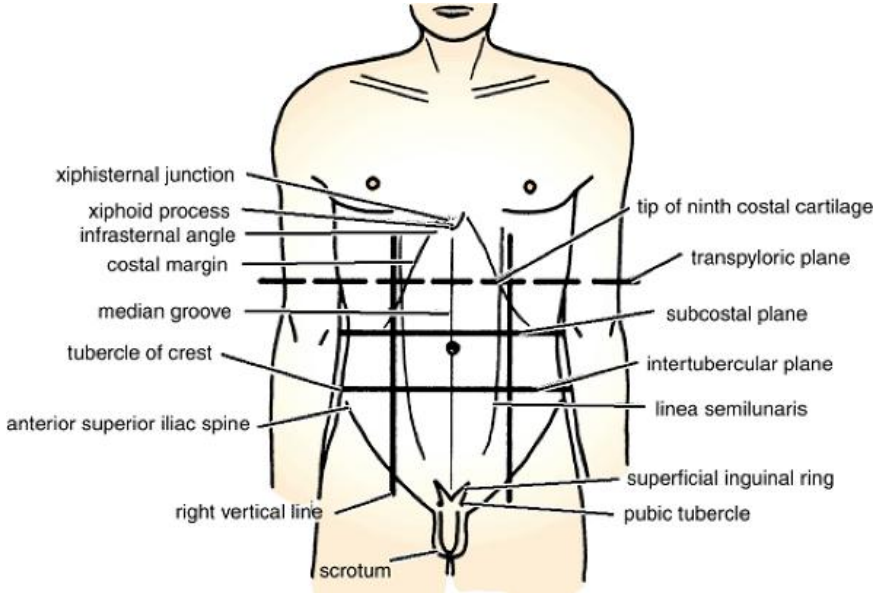

ABDOMINAL REGIONS:

According to right and left vertical planes and subcostal and intertubercular planes into:

1. Right hypochondrium
2. Epigastrium
3. Left hypochondrium
4. Right lumbar
5. Umbilical
6. Left lumbar
7. Right iliac
8. Hypogastrium
9. Left iliac

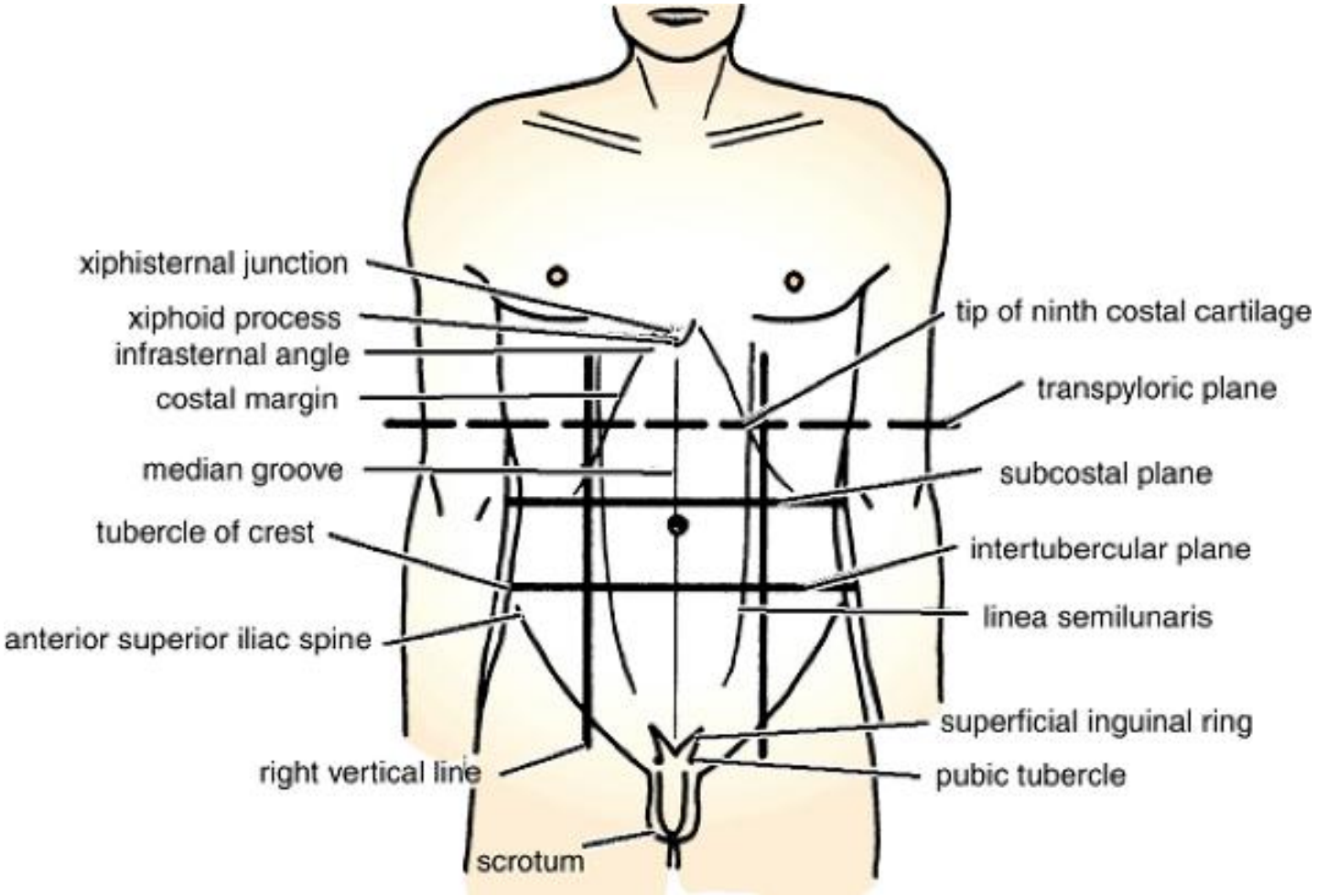

ABDOMINAL QUADRANTS:

- Divide up the abdomen into quadrants by using a vertical and a horizontal line that intersect at the umbilicus.

They are:

1. Upper right
2. Upper left
3. Lower right
4. Lower left

Epigastrium: Area below xiphoid process and above umbilicus.

Periumbilical: Area around umbilicus.

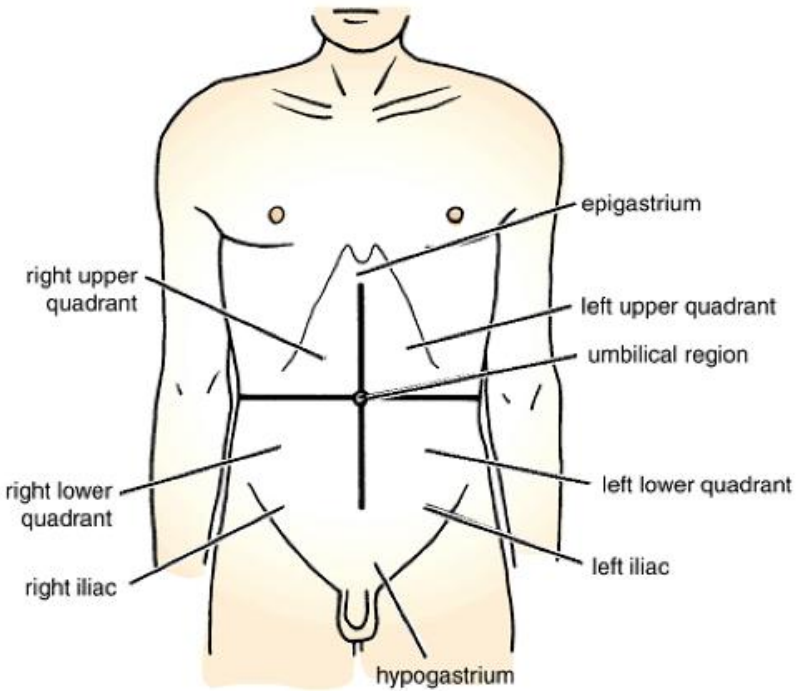

PEROTONEUM

Serous membrane lining walls of abdominal and pelvic cavities and clothing abdominal and pelvic viscera.

Consists of:

1. Parietal peritoneum:

Lines walls of abdominal and pelvic cavities.

2. Visceral peritoneum: Covers the organs

3. Peritoneal cavity:

- Space between parietal and visceral layers
- Closed cavity in males
- In females, connected with the exterior through uterine tubes, uterus and vagina.
- **Can be divided into:** Greater sac and lesser sac

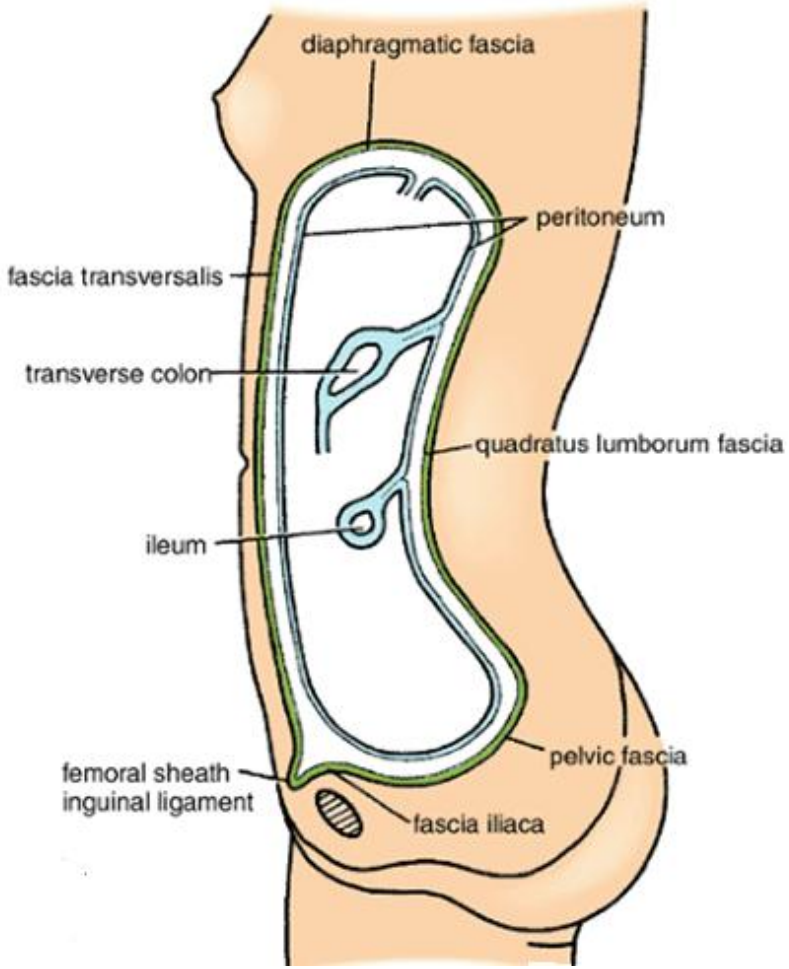

Greater sac:

- Main compartment of peritoneal cavity.
- Extends from diaphragm down to pelvic cavity.

Lesser sac: Smaller, lies behind stomach.

Peritoneal fluid:

- Small amount of serous fluid, which lubricates surfaces of the peritoneum and allows free movement between the viscera.

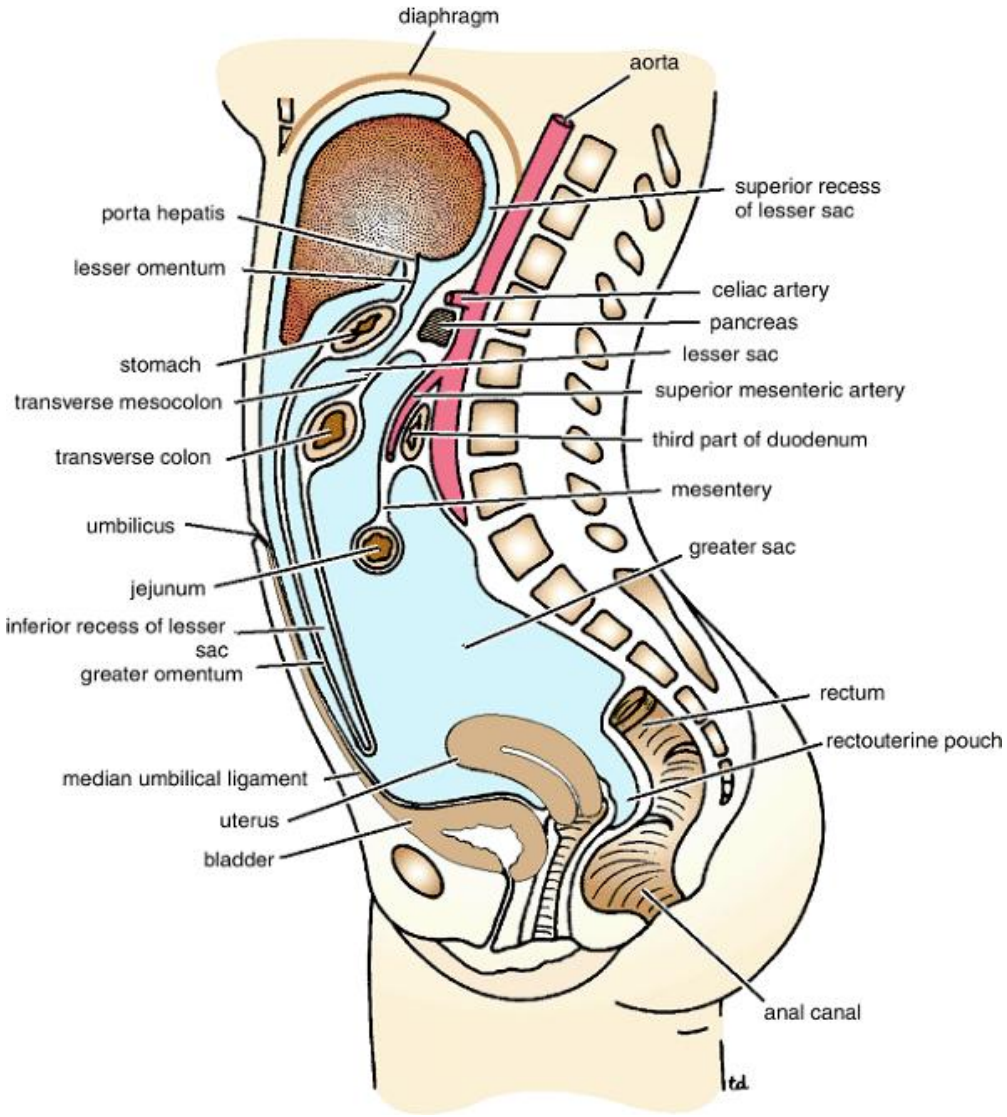

INTRAPERITONEAL and RETROPERITONEAL RELATIONSHIPS:

INTRAPERITONEAL:

When an organ almost totally covered with visceral peritoneum.

Examples of intraperitoneal organs:

1. Stomach
2. Jejunum
3. Ileum
4. Spleen

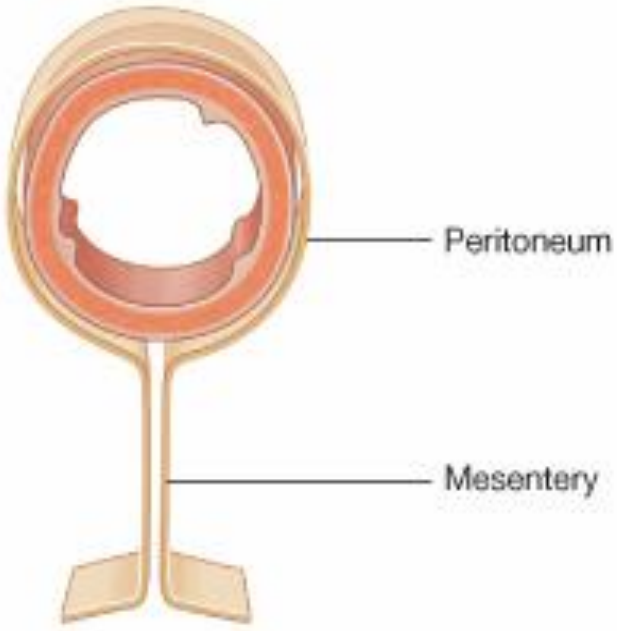

RETROPERITONEAL ORGANS:

Definition:

The organs which lie behind peritoneum, only partially covered with visceral peritoneum.

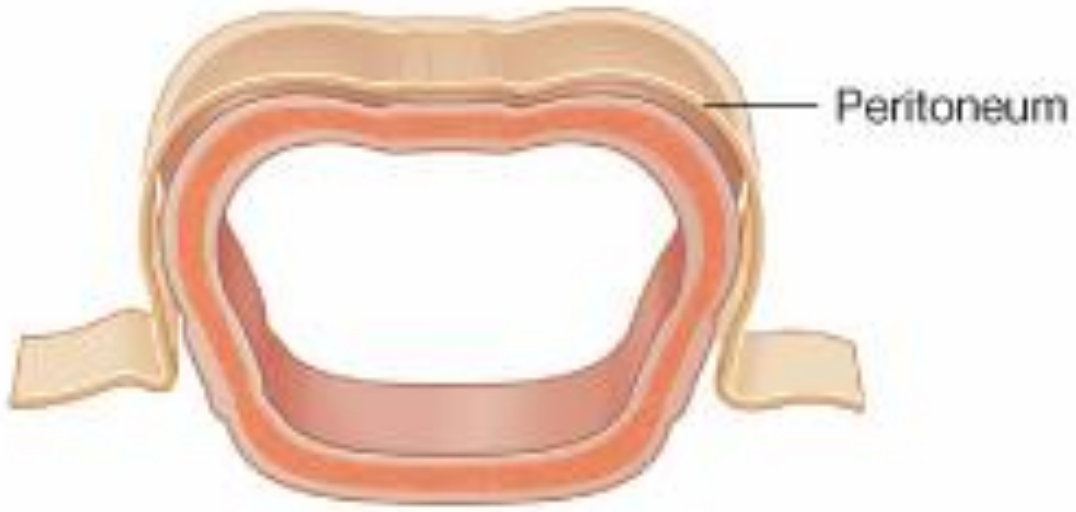

Examples of retroperitoneal organs:

1. Pancreas
2. Ascending part of the colon
3. Descending part of the colon

Notes:

- No organ, is actually within the peritoneal cavity.
- An intraperitoneal organ as the stomach appears to be surrounded by peritoneal cavity, but covered with visceral peritoneum and attached to other organs by omenta.

Peritoneal Ligaments, Omenta And Mesenteries

Peritoneal Ligaments:

- Two-layered folds of peritoneum that connect solid viscera to abdominal walls.
- *Have not dense fibrous tissue seen in ligaments associated with bones.*

Example:

Falciform Ligament:

- Connects the liver to diaphragm and anterior abdominal wall.

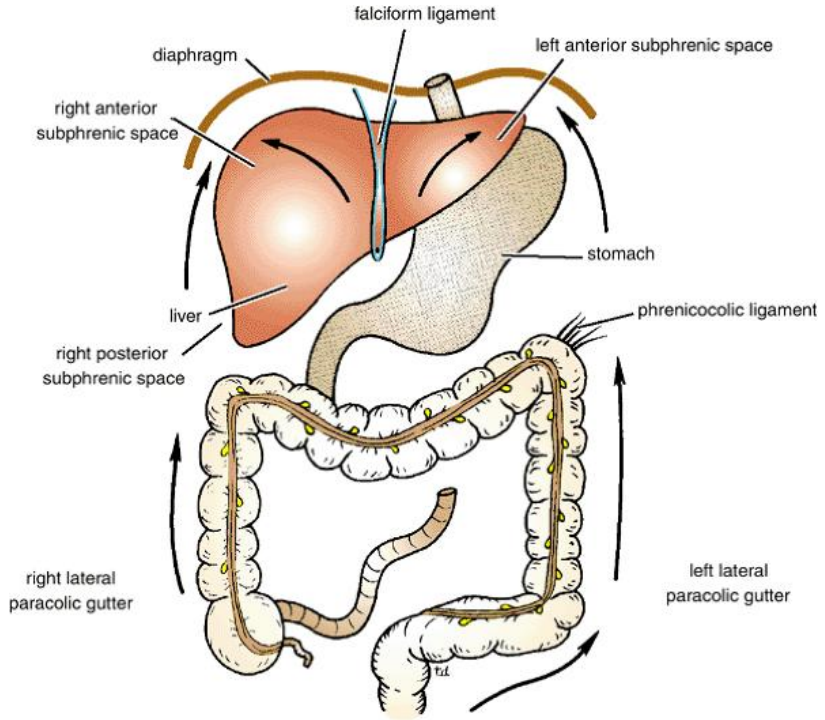

Omenta

- Two-layered folds of peritoneum that connect the stomach to another viscus.

Greater omentum:

- Connects greater curvature of stomach to transverse colon.
- Hangs down in front of coils of small intestine
- Folded back on itself to be attached to the transverse colon.

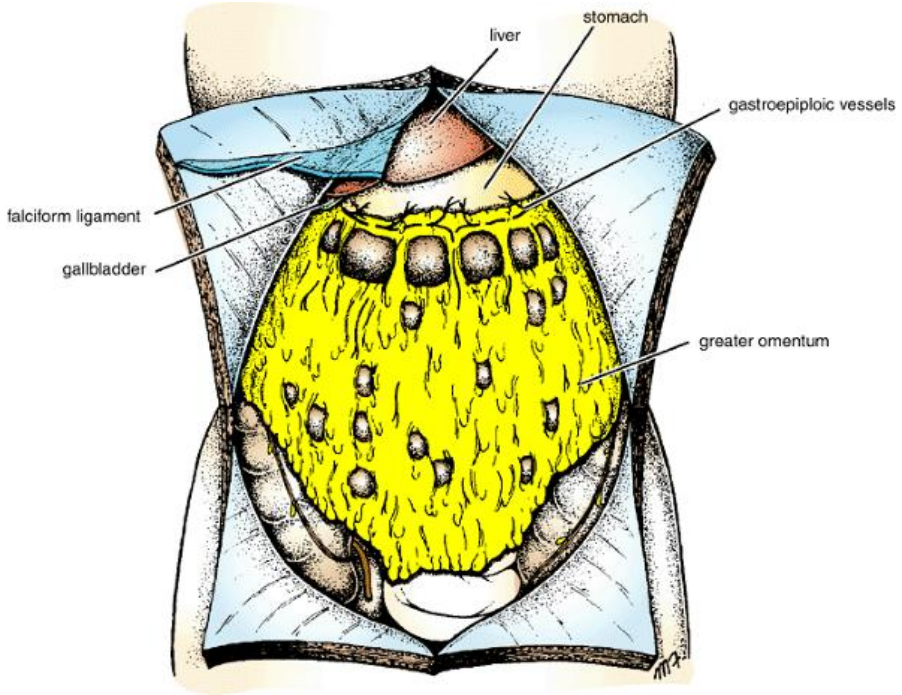

Lesser omentum:

- Suspends lesser curvature of the stomach to under-surface of the liver.

Gastrosplenic omentum (ligament):

- Connects the stomach to hilum of the spleen.

Mesenteries:

Definition: Two-layered folds of peritoneum connecting parts of intestines to posterior abdominal.

Examples of mesenteries:-

1. Mesentery of small intestine
2. Transverse mesocolon
3. Sigmoid mesocolon

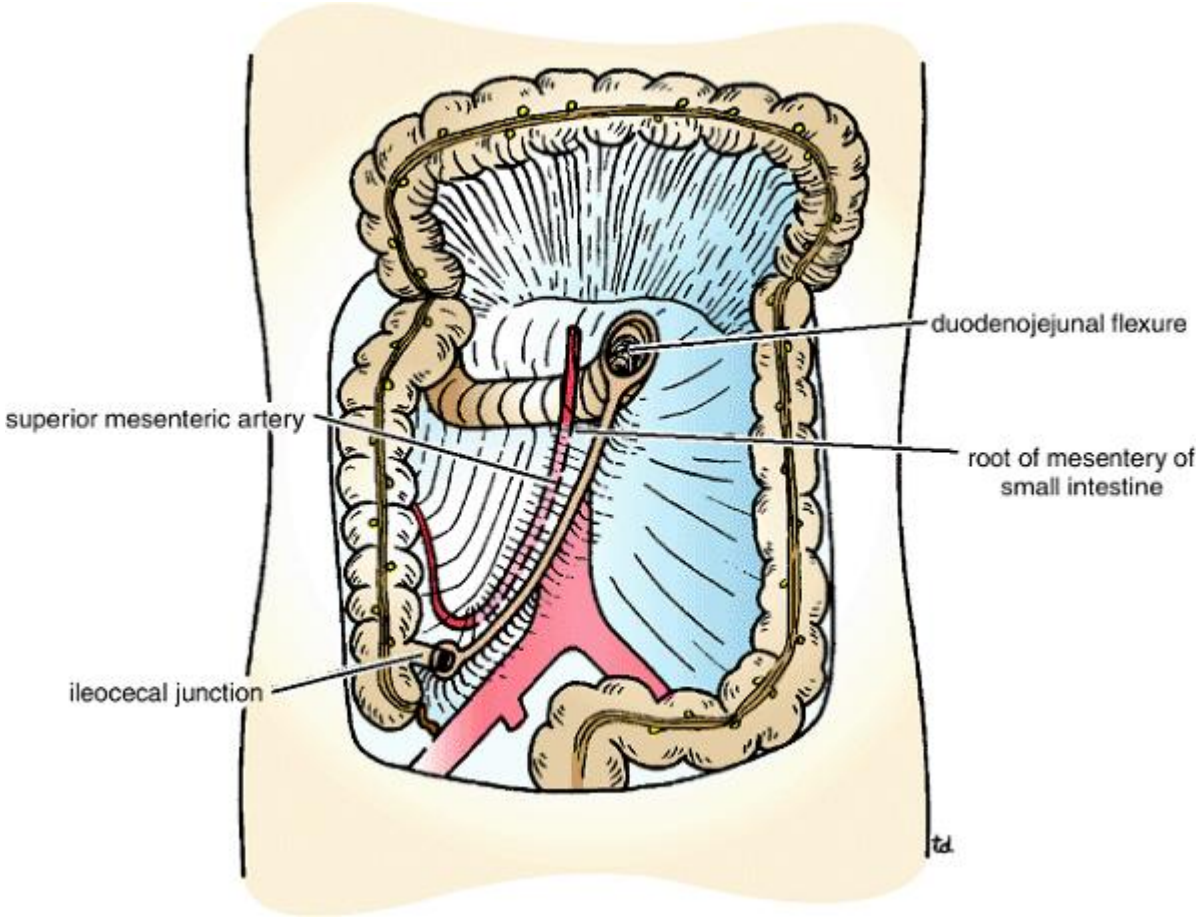

EPIPLOIC FORAMEN

Epiploic foramen (opening of lesser sac):

Oval window between greater and lesser sacs

Boundaries of epiploic foramen:

Anteriorly: Free margin of lesser omentum containing bile duct (right ad in front), hepatic artery (left and in front) and portal vein (posteriorly)

Posteriorly: Inferior vena cava

Superiorly: Caudate process of the liver

Inferiorly: 1st part of duodenum

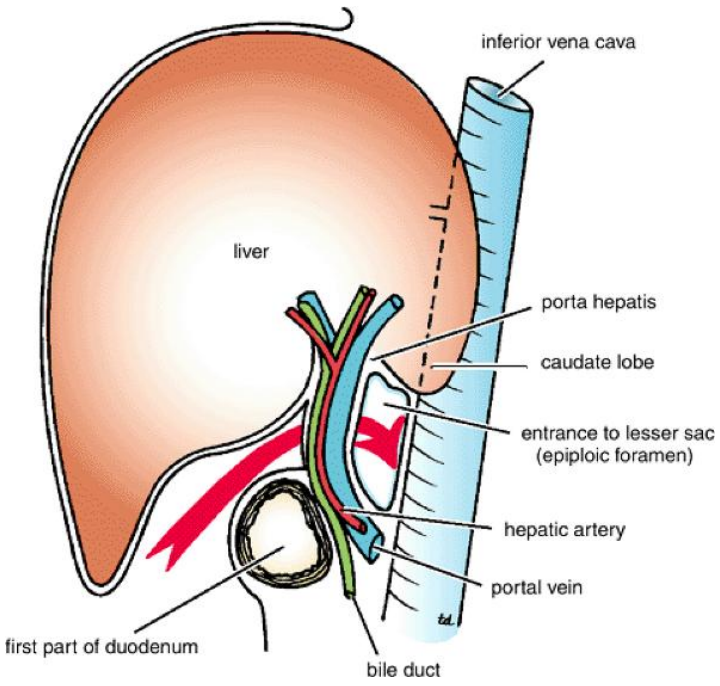

SUBPHRENIC SPACES:

1. Right anterior subphrenic spaces: Lie between diaphragm and liver on right side of the falciform ligament.

2. Left anterior subphrenic spaces: Lie between diaphragm and liver on left side of the falciform ligament.

3. Right posterior subphrenic space: Lies between right lobe of liver, right kidney and right colic flexure.

4. Right extraperitoneal space: Lies between layers of coronary ligament (between liver and diaphragm.

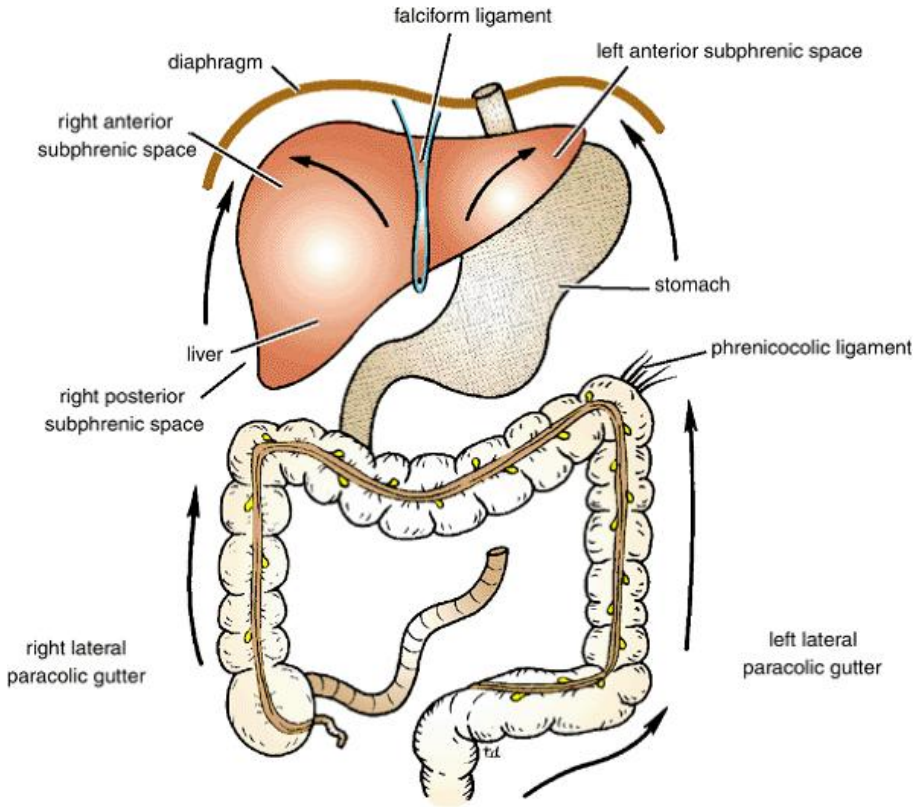

PARACOLIC GUTTERS (4):

Lie: On lateral and medial sides of ascending and descending colons.

1. **Right medial paracolic gutter: Closed off from pelvic cavity by mesentery of small intestine (others has free communication).**

2. Right lateral paracolic gutter: In communication with right posterior subphrenic space.

3. Left lateral paracolic gutter: Separated from area around the spleen by phrenicocolic ligament (fold of peritoneum between left colic flexure and diaphragm).

4. Left medial paracolic gutter: Has free communication with pelvic cavity.

Direction of flow of the peritoneal fluid:

1. Normal flow upward to the subphrenic spaces.

2. Flow of inflammatory exudate in peritonitis.

3. The two sites where inflammatory exudate tends to collect when the patient is nursed in the supine position.

4. Accumulation of inflammatory exudate in the pelvis when the patient is nursed in the inclined position.

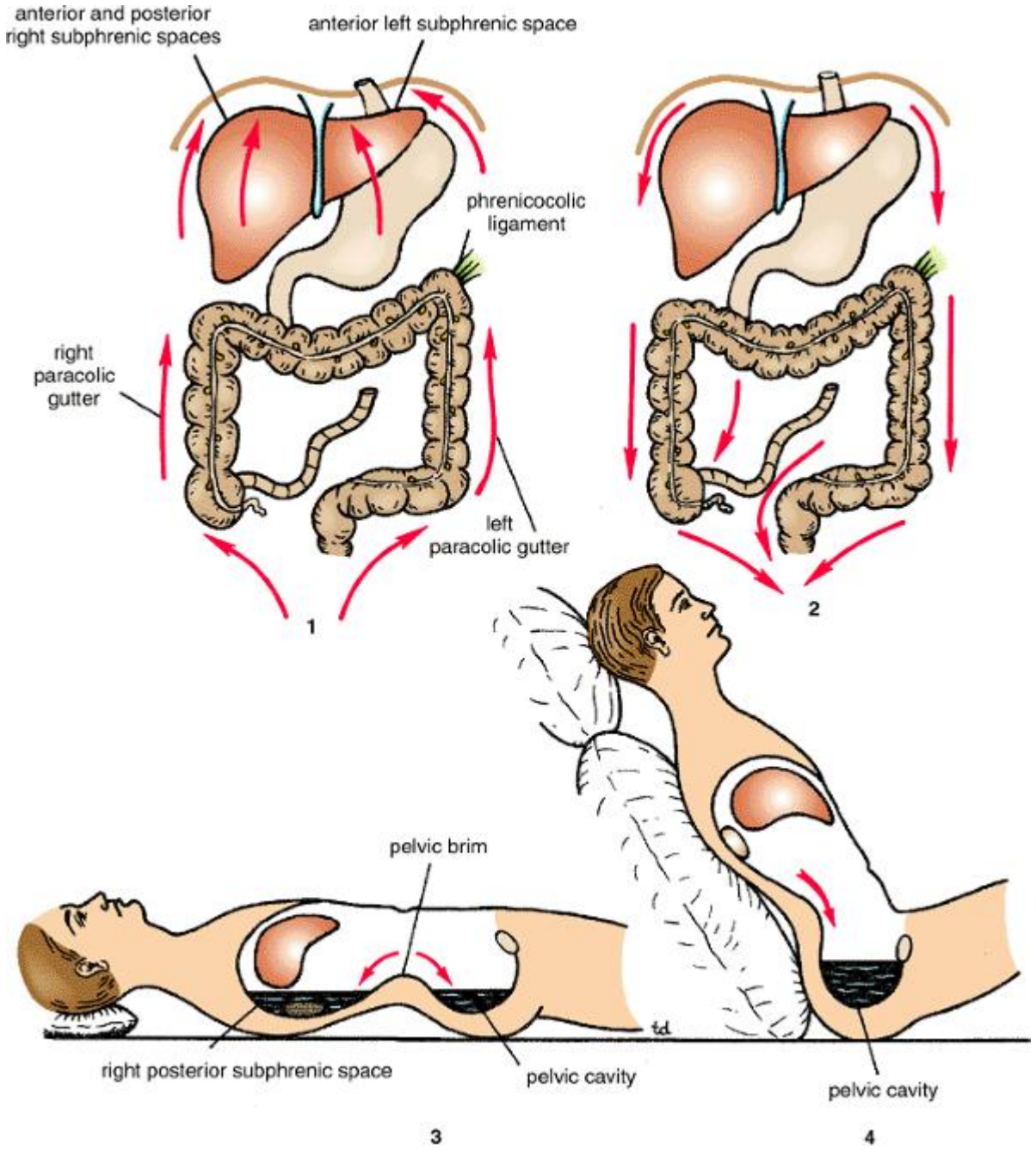

NERVE SUPPLY OF PERITONEUM

1. Parietal peritoneum: As structure lined

Sensitive to: Pain, temp, touch and pressure

Lining anterior abdominal wall: Lower 6 thoracic and 1st lumbar nerves

Central part of diaphragmatic peritoneum: Phrenic nerves

Peripherally, diaphragmatic peritoneum: Lower 6 thoracic nerves

In pelvis: Obturator nerves

2. Visceral peritoneum: As viscera covered

Sensitive only to stretch and tearing

Supplied by: Autonomic afferent nerves

Over distension of viscus→sensation of pain

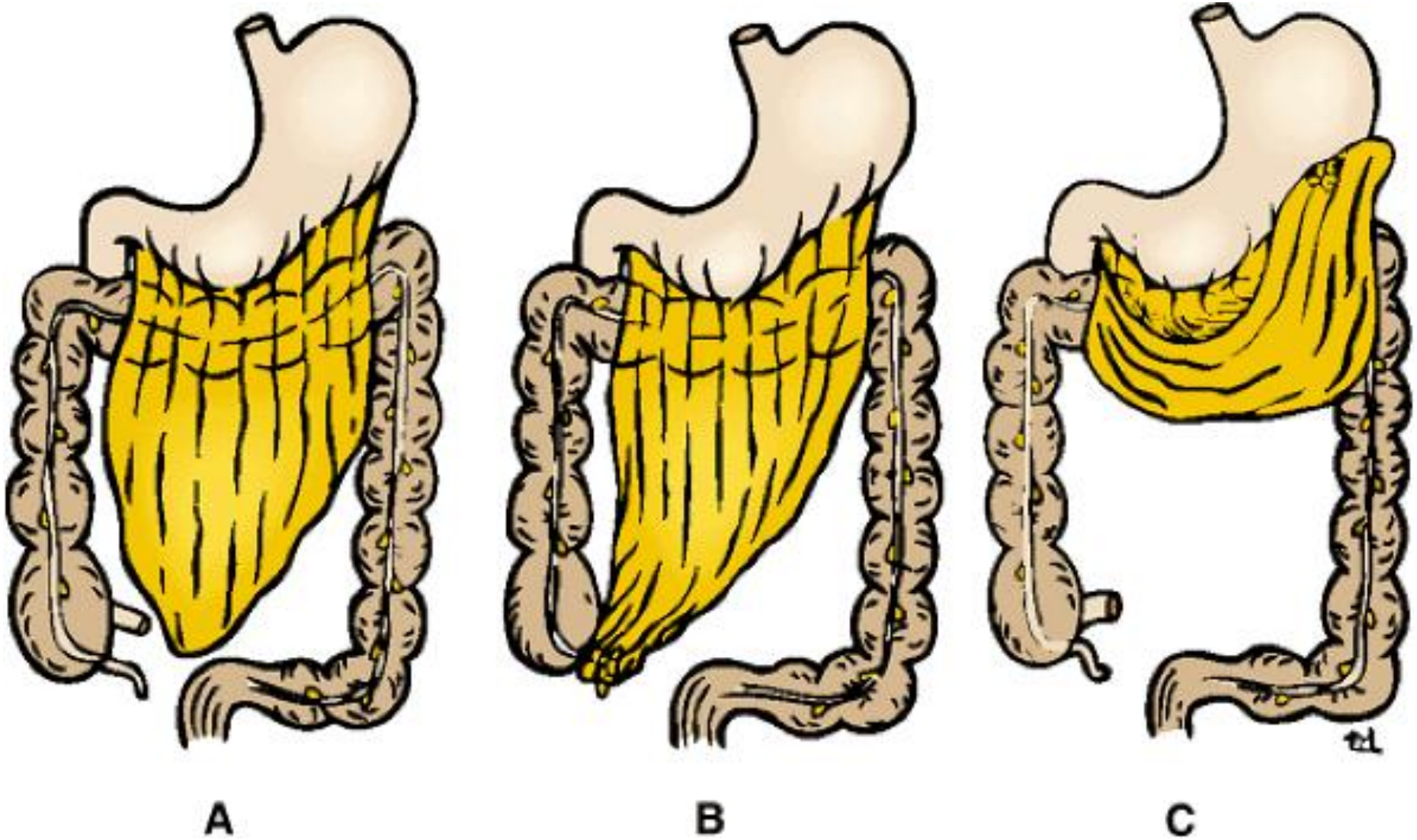

A. The normal greater omentum.
B. The greater omentum wrapped around an inflamed appendix.
C. The greater omentum adherent to the base of a gastric ulcer. One important function of the greater omentum is to attempt to limit the spread of intraperitoneal infections.

Thank You